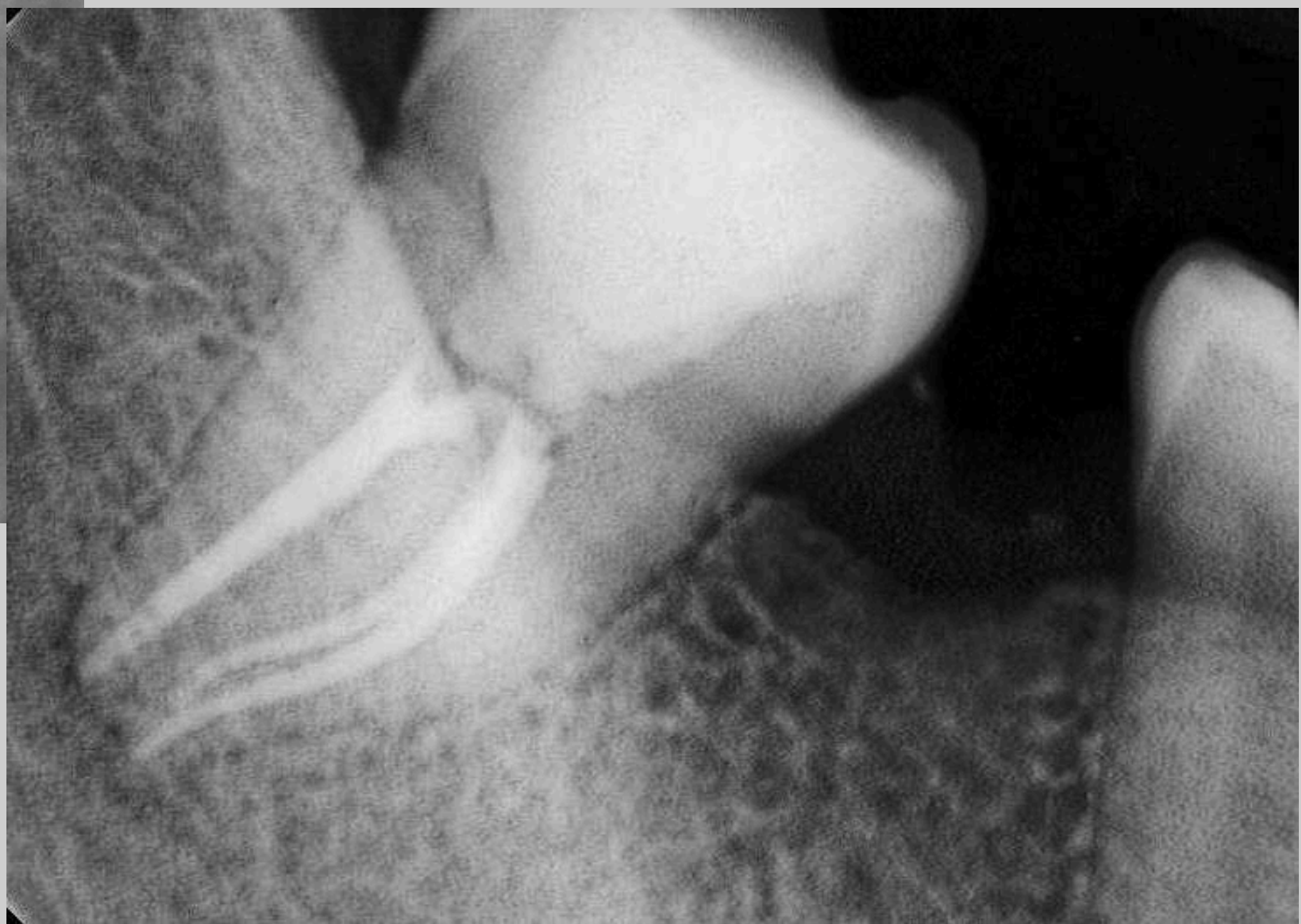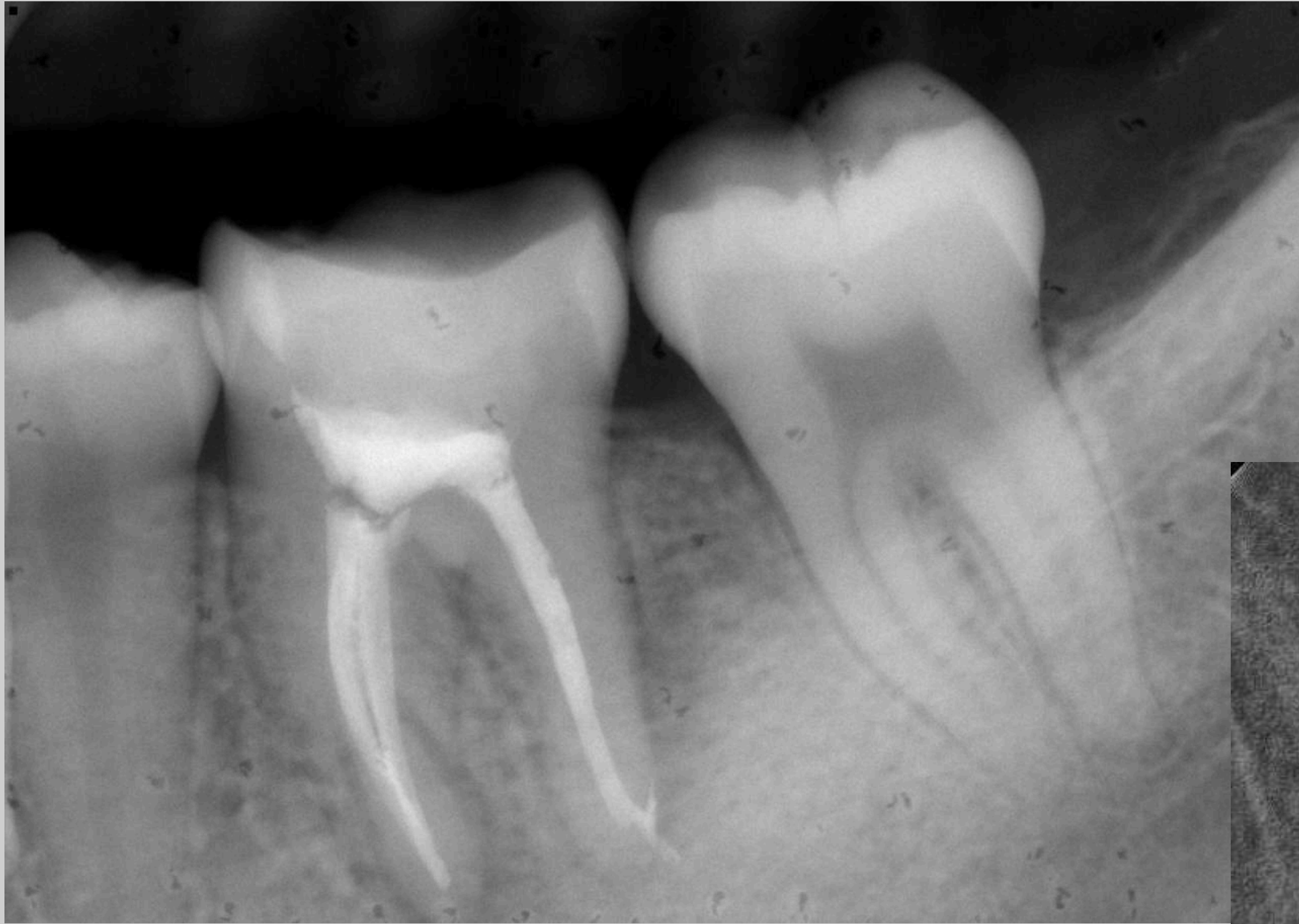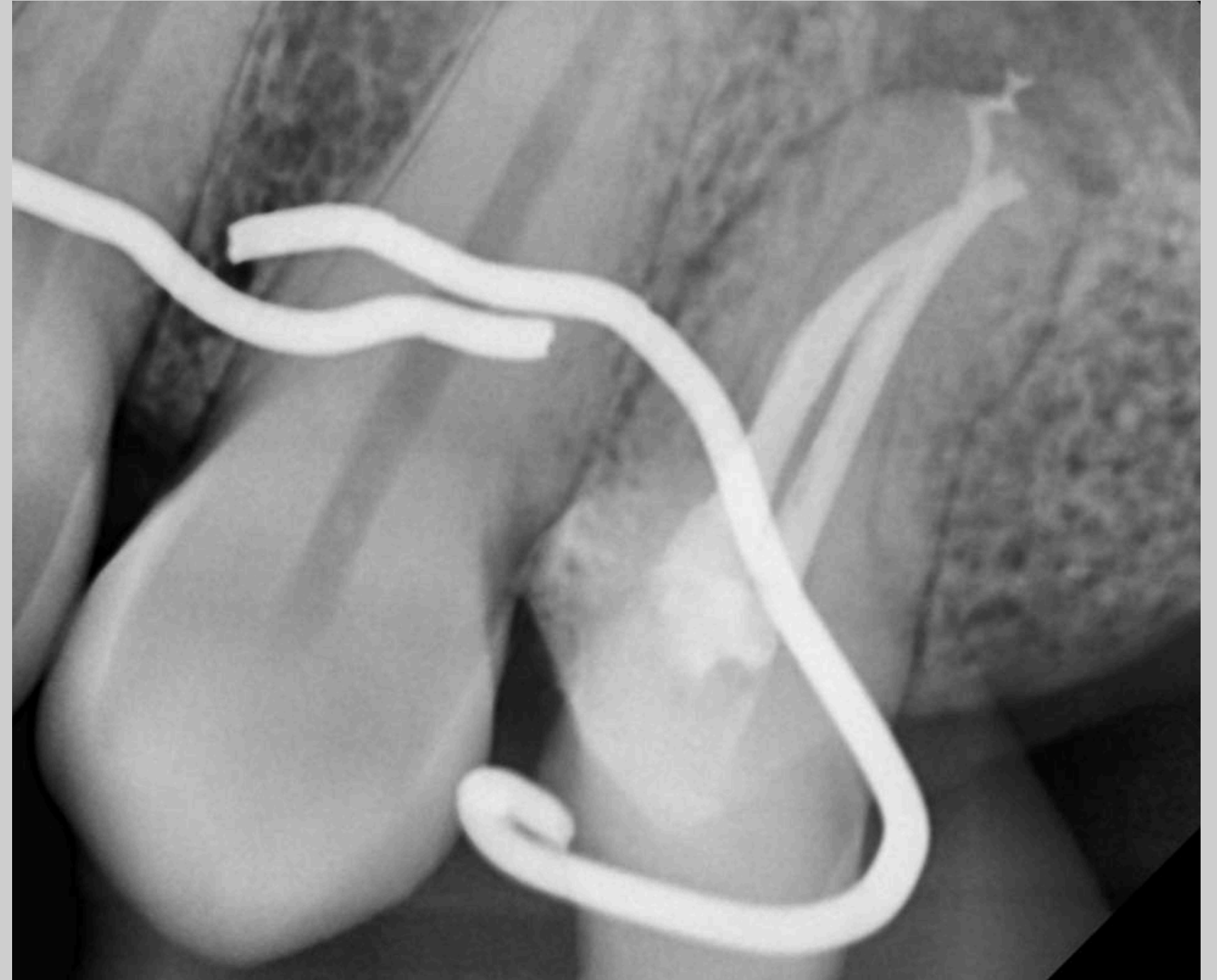
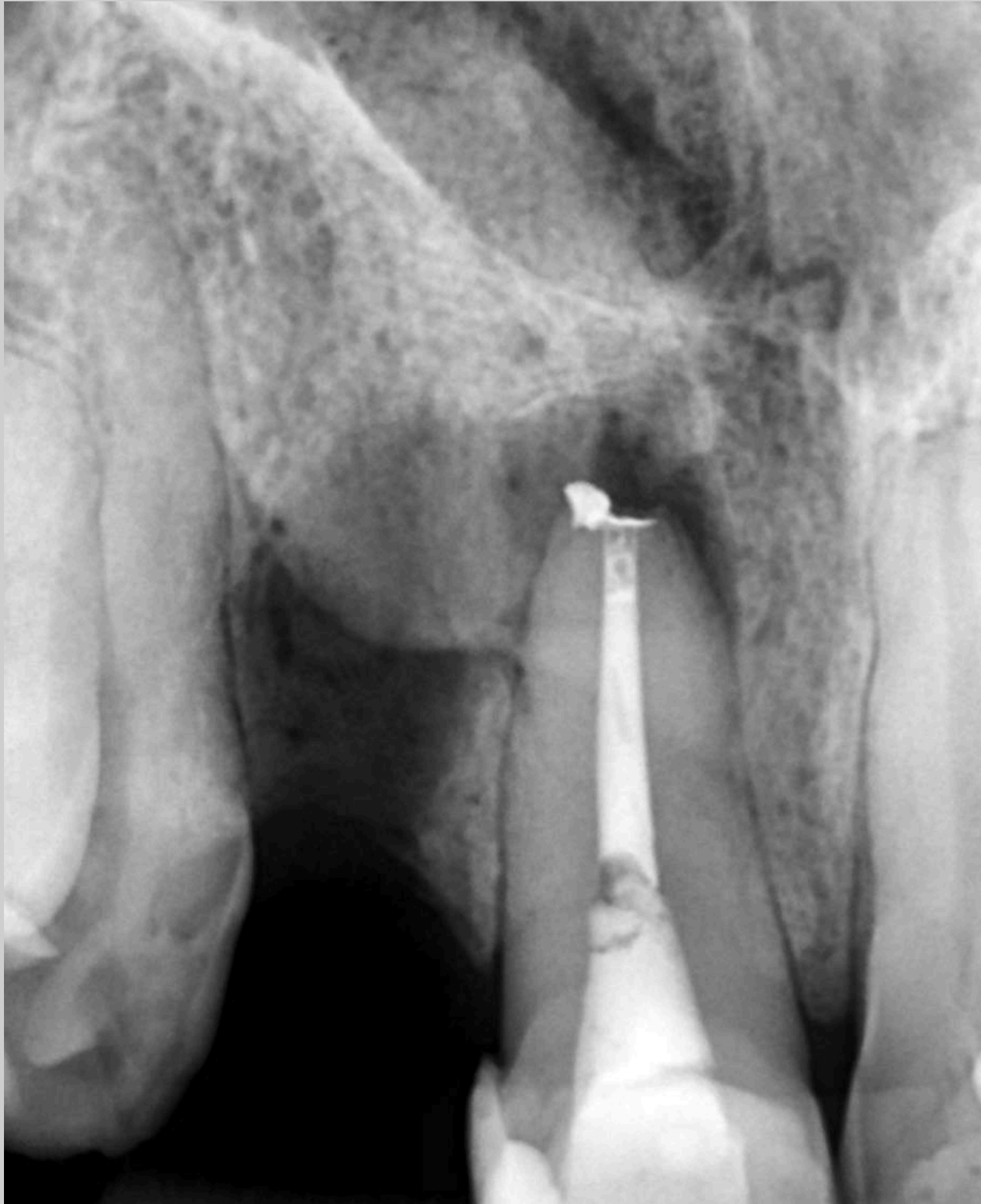




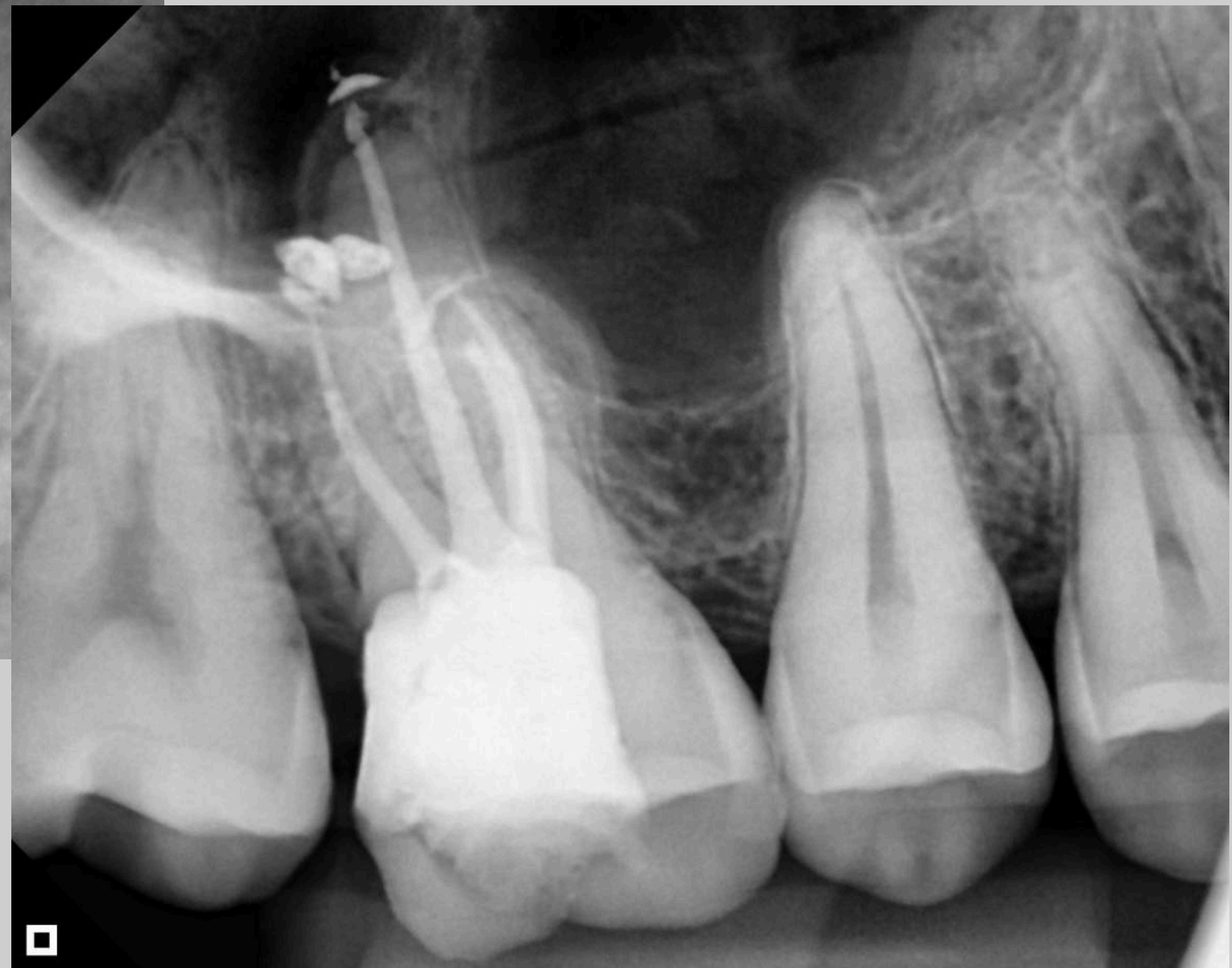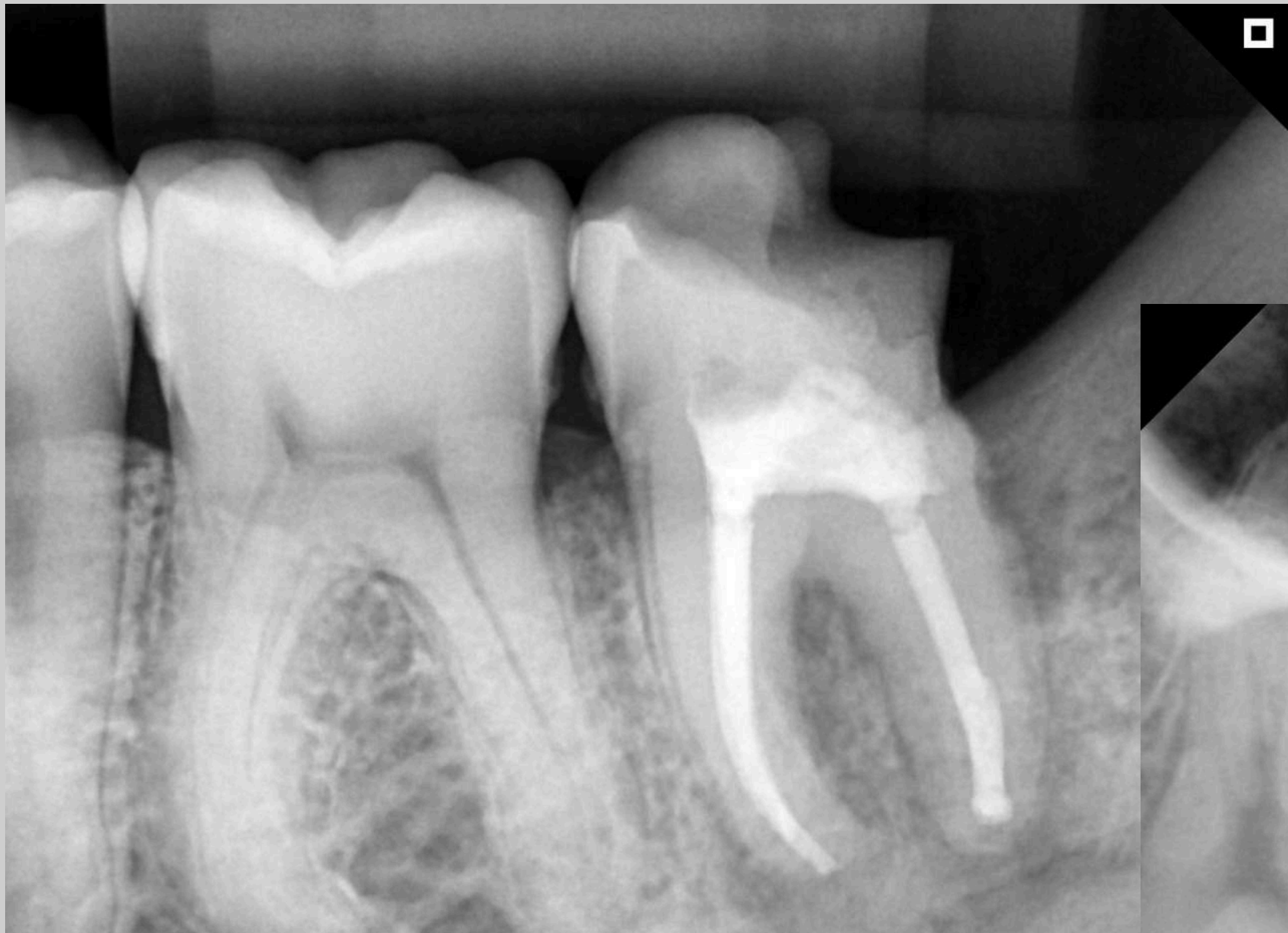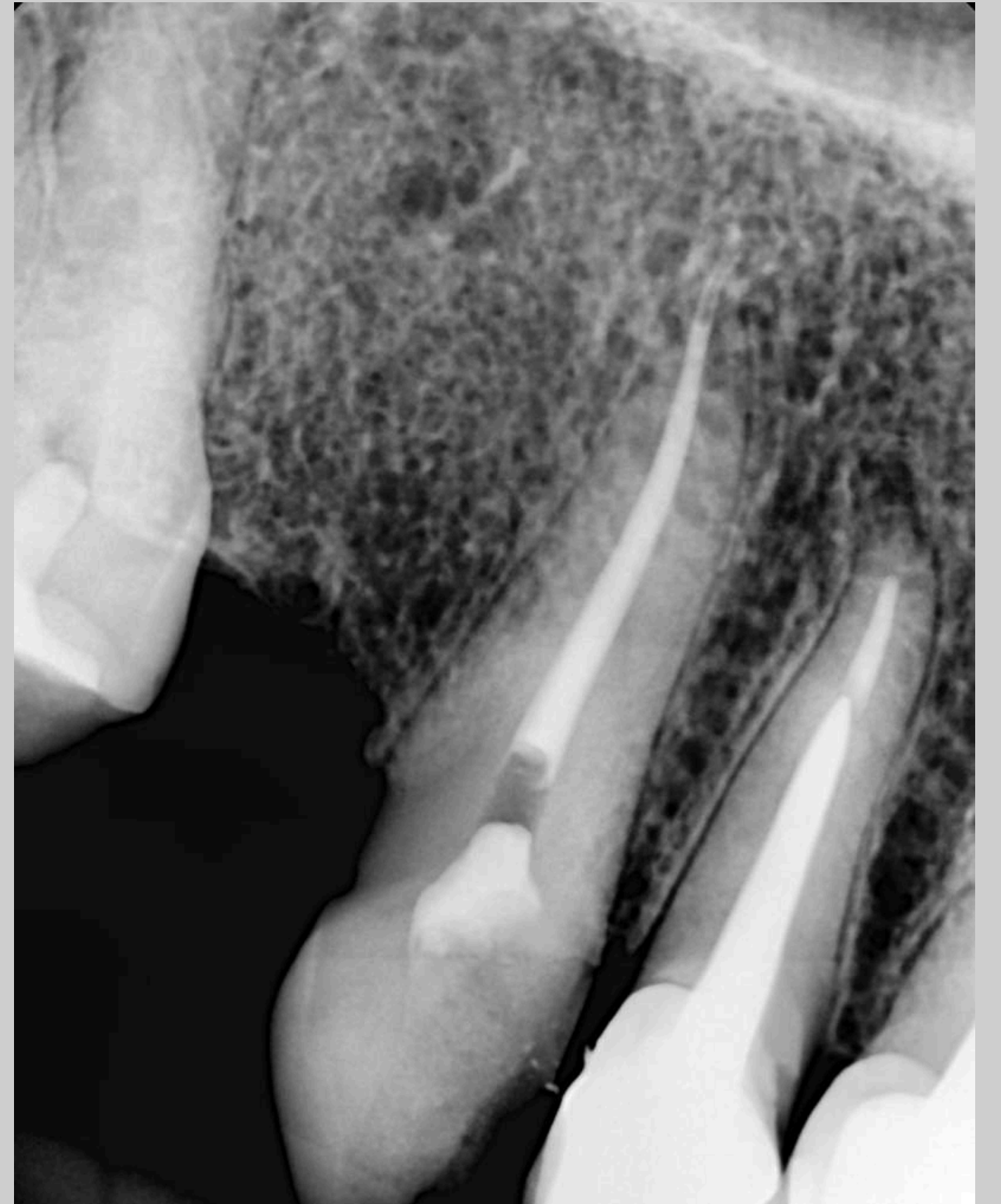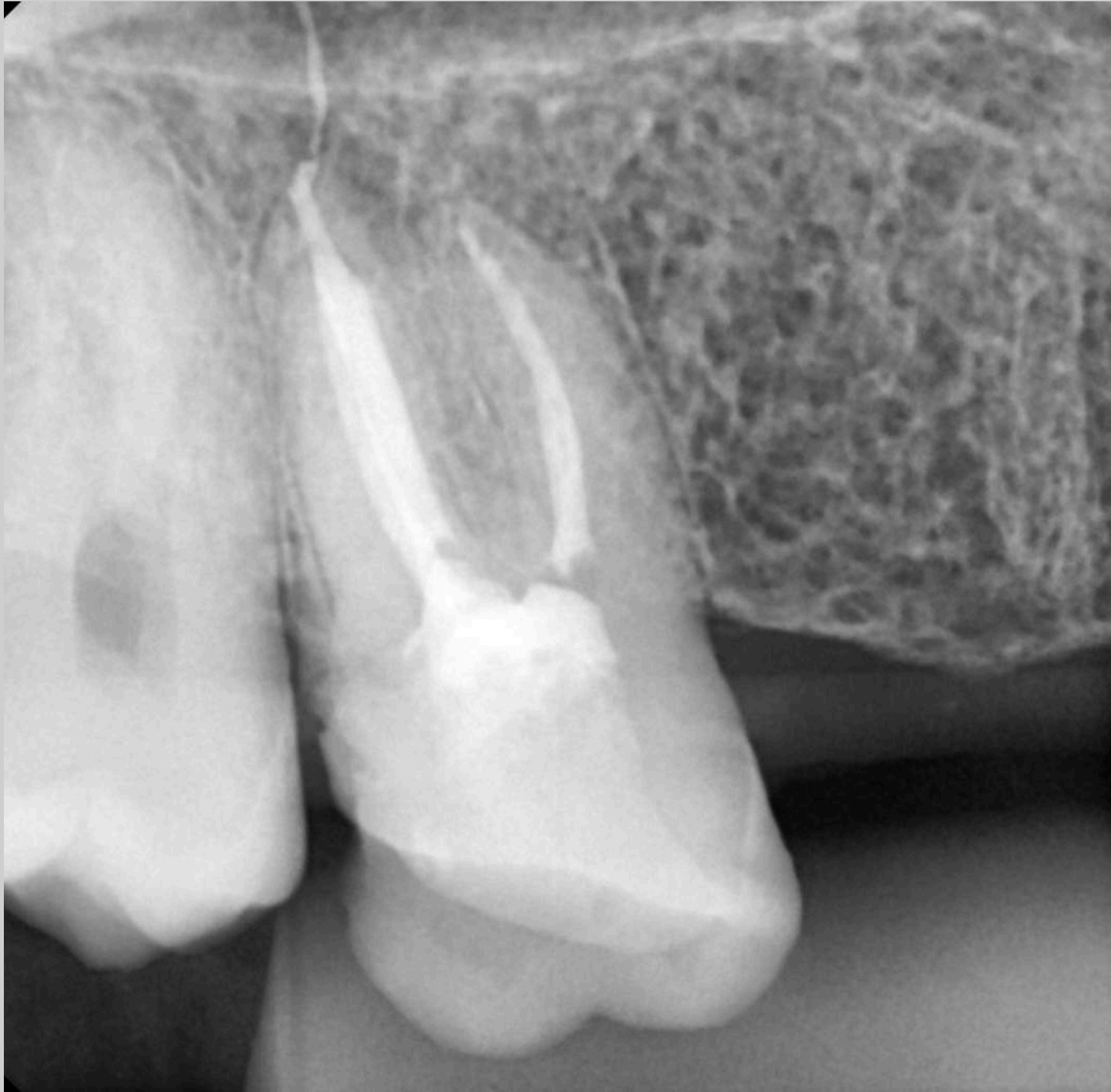Dra. Maria Eduarda
ENDONDONTIA MECANIZADA

CRO/SC 20774

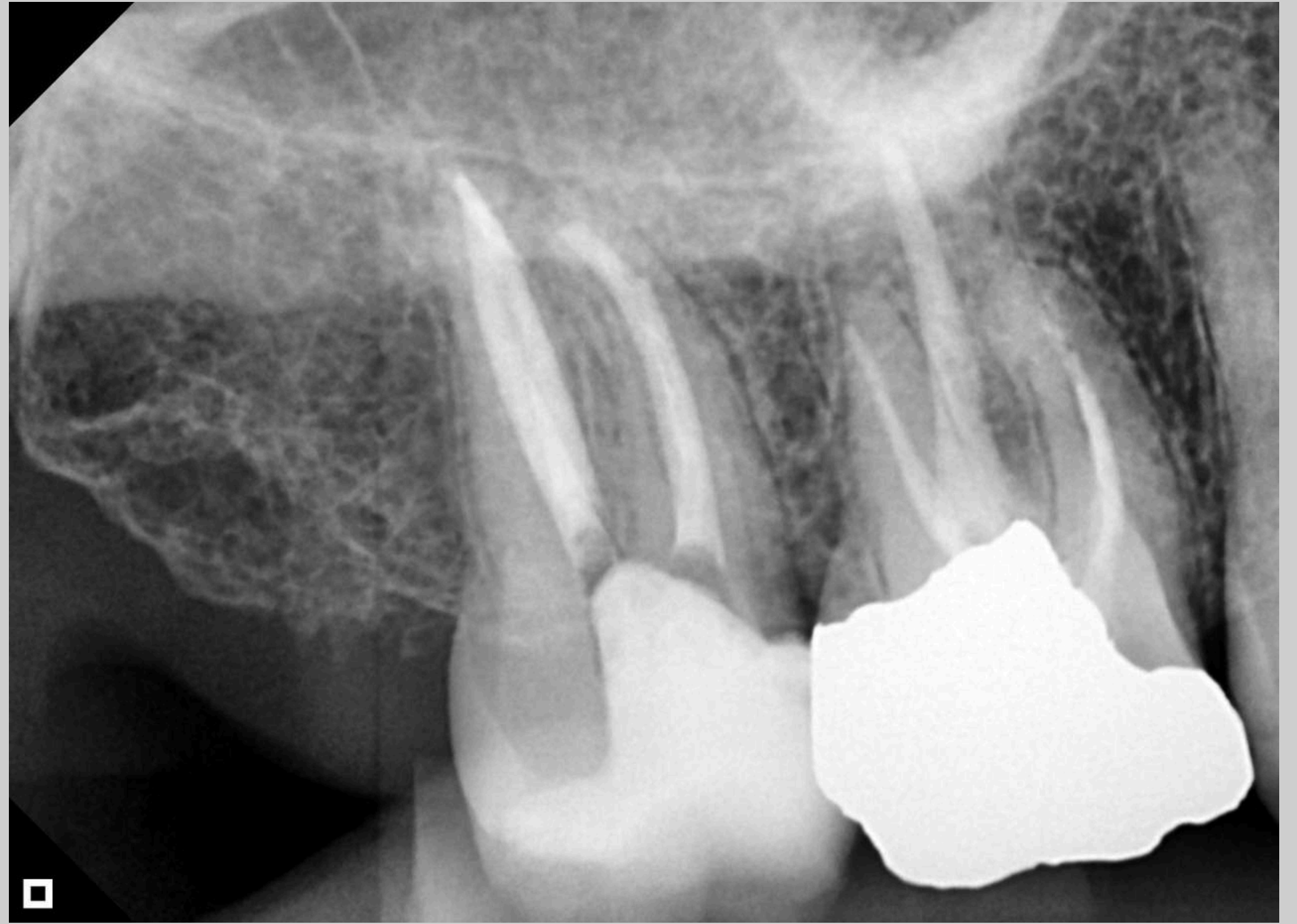
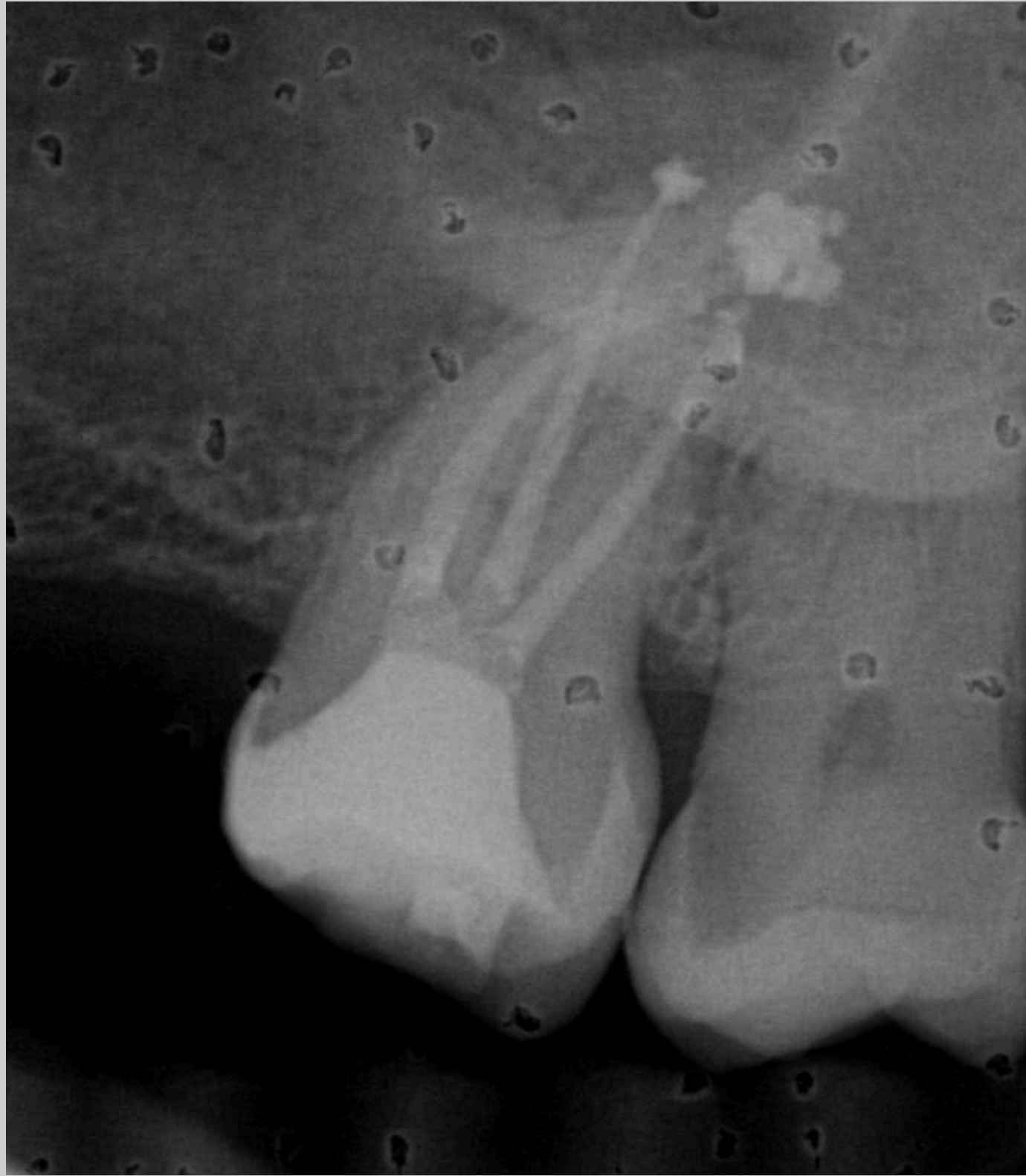




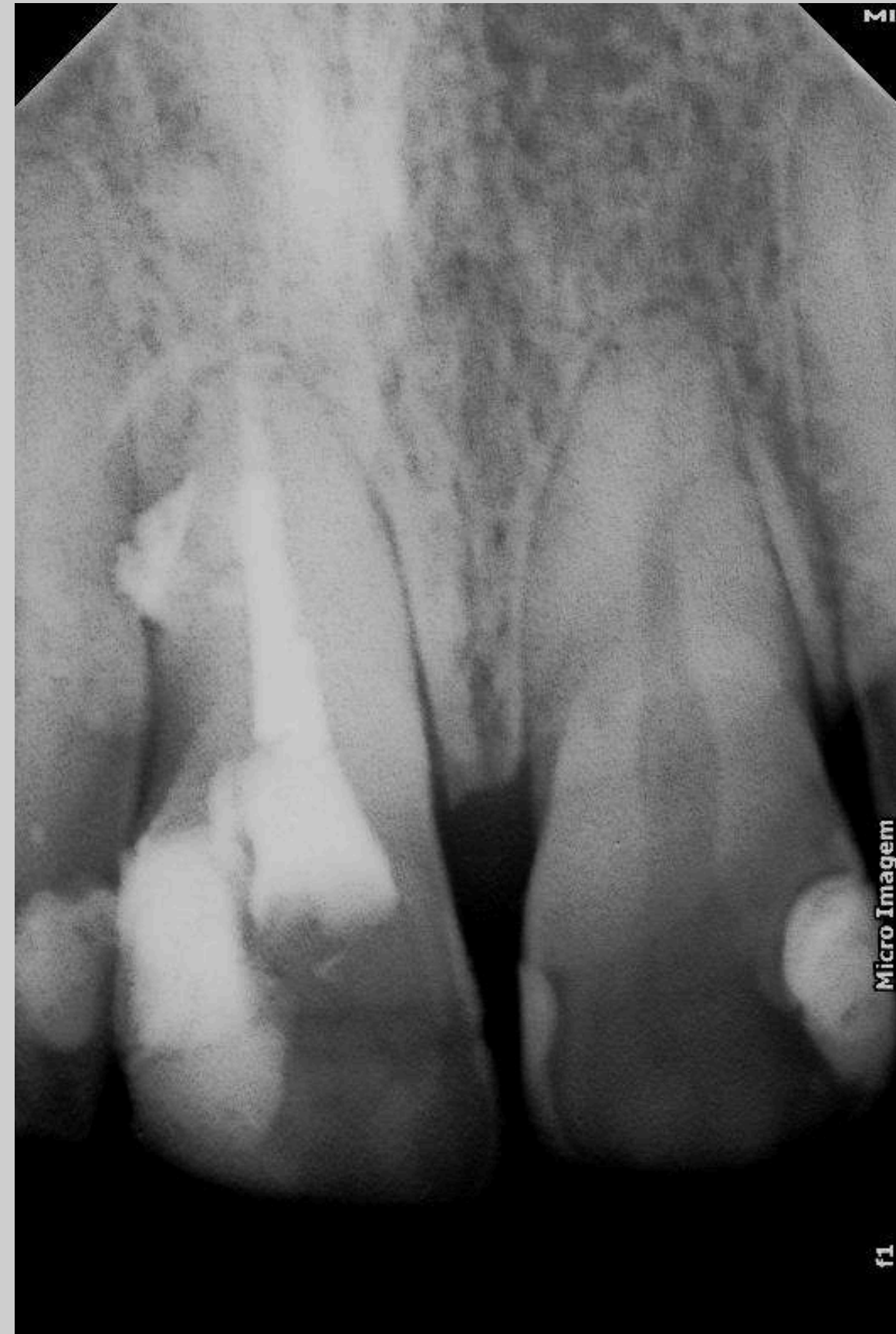
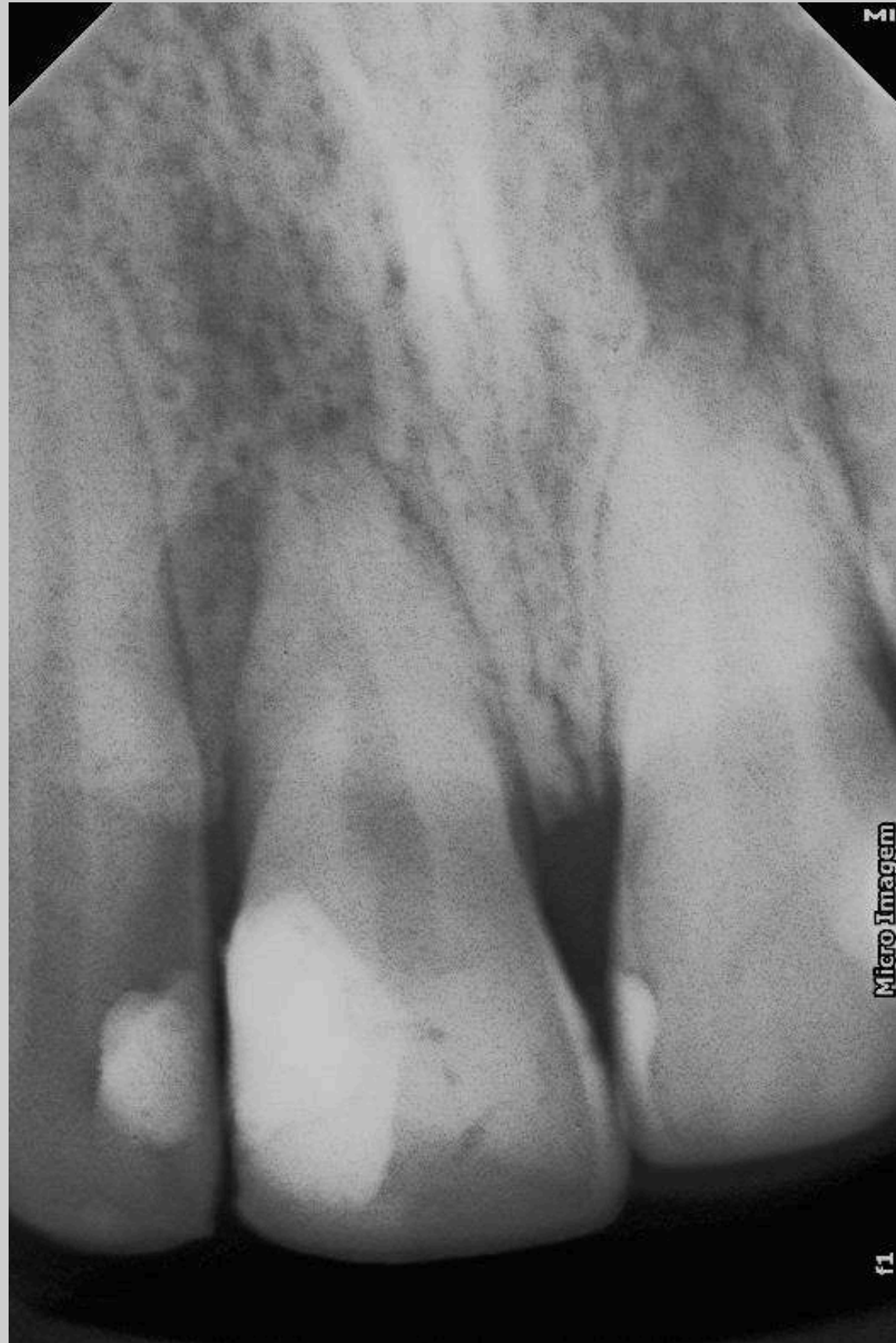

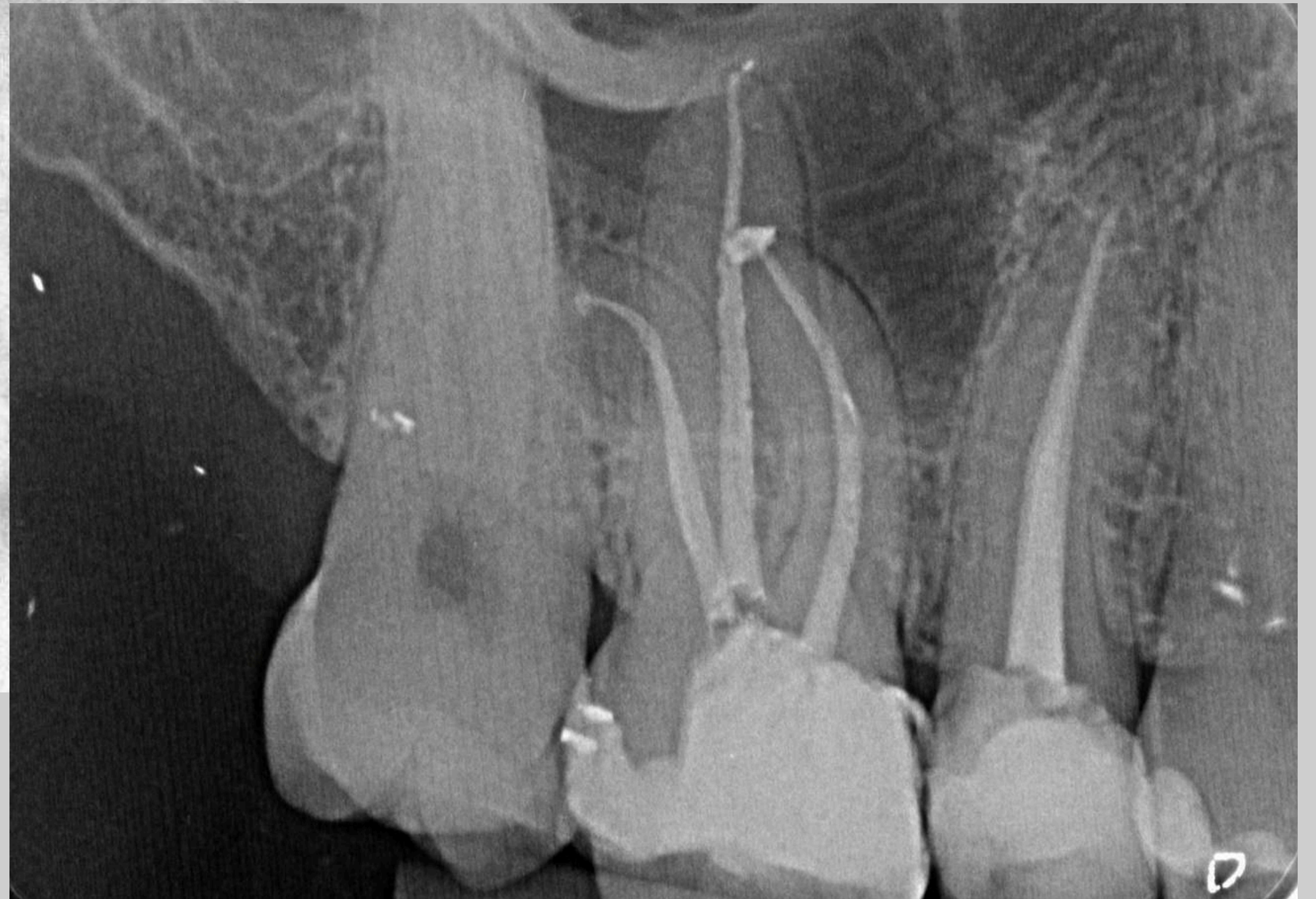
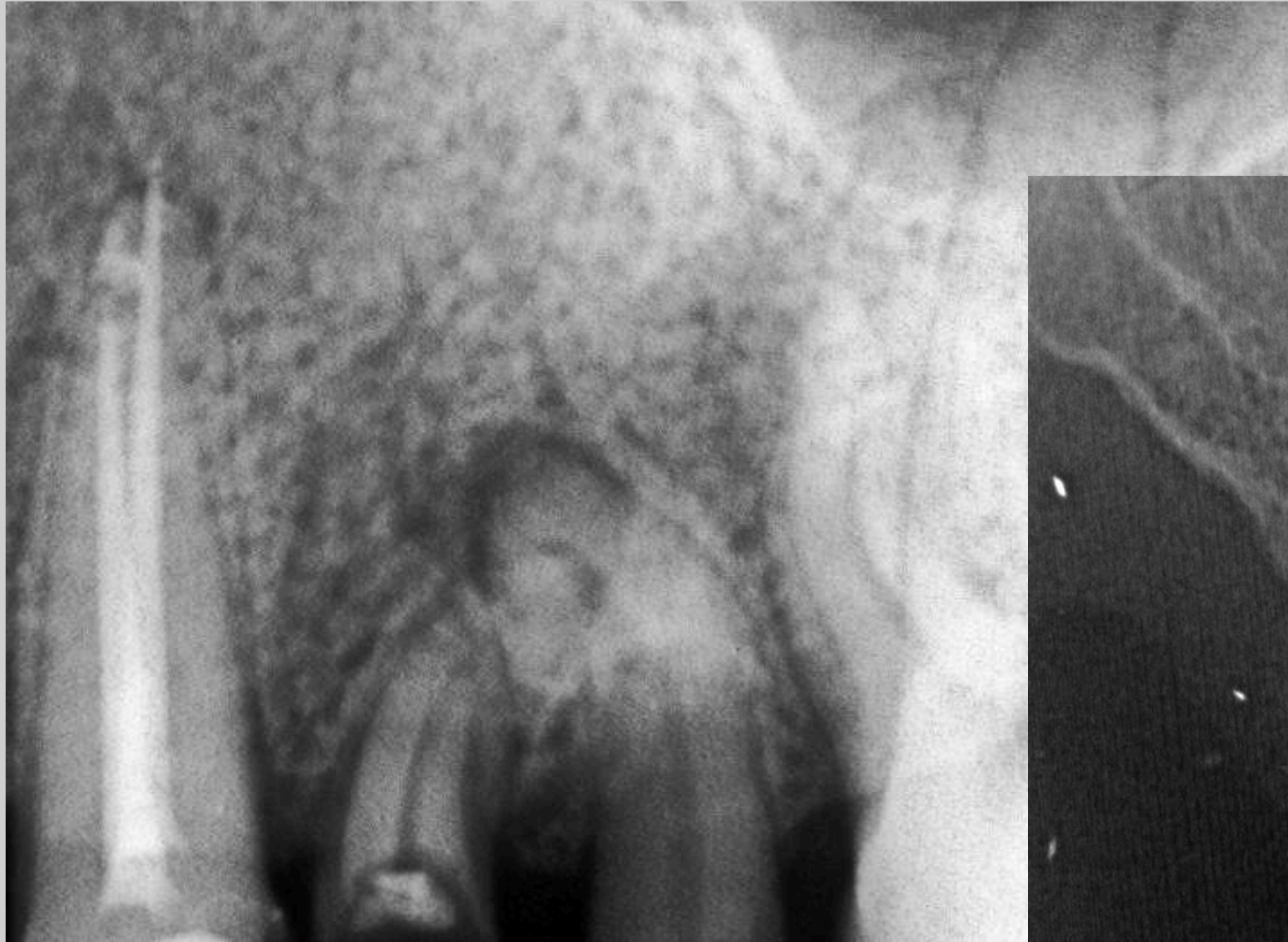Elemento 13



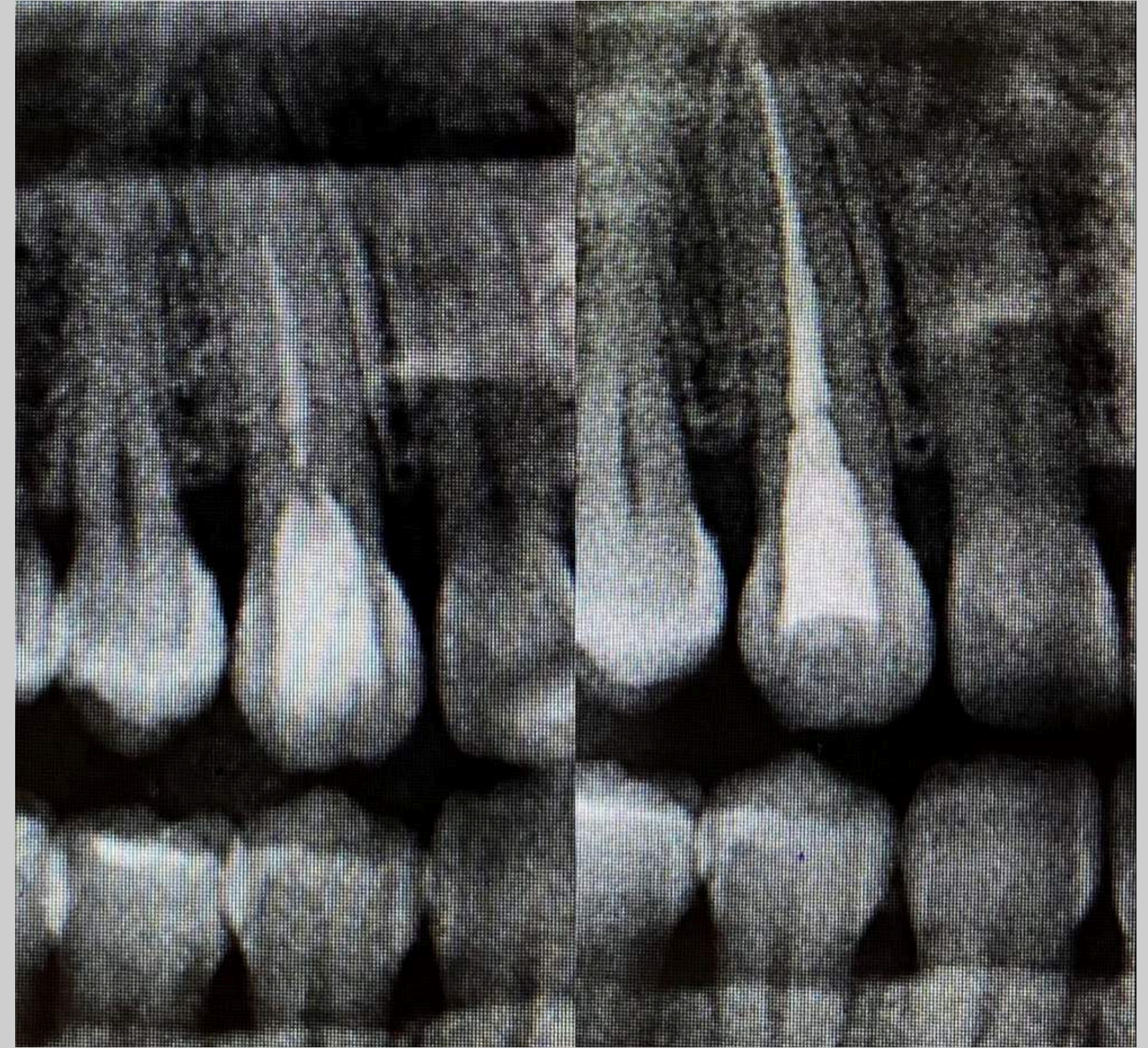
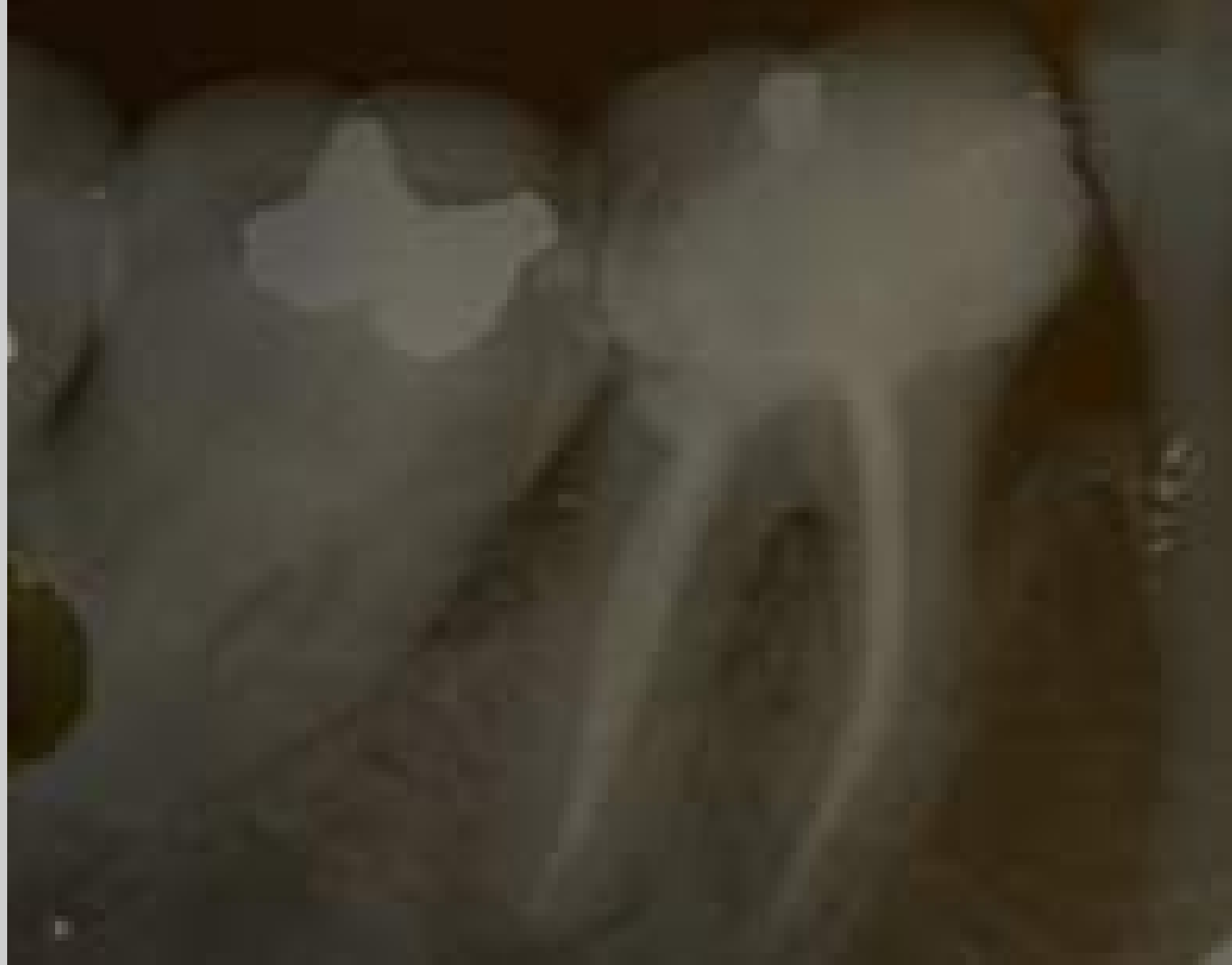Eelemento 17



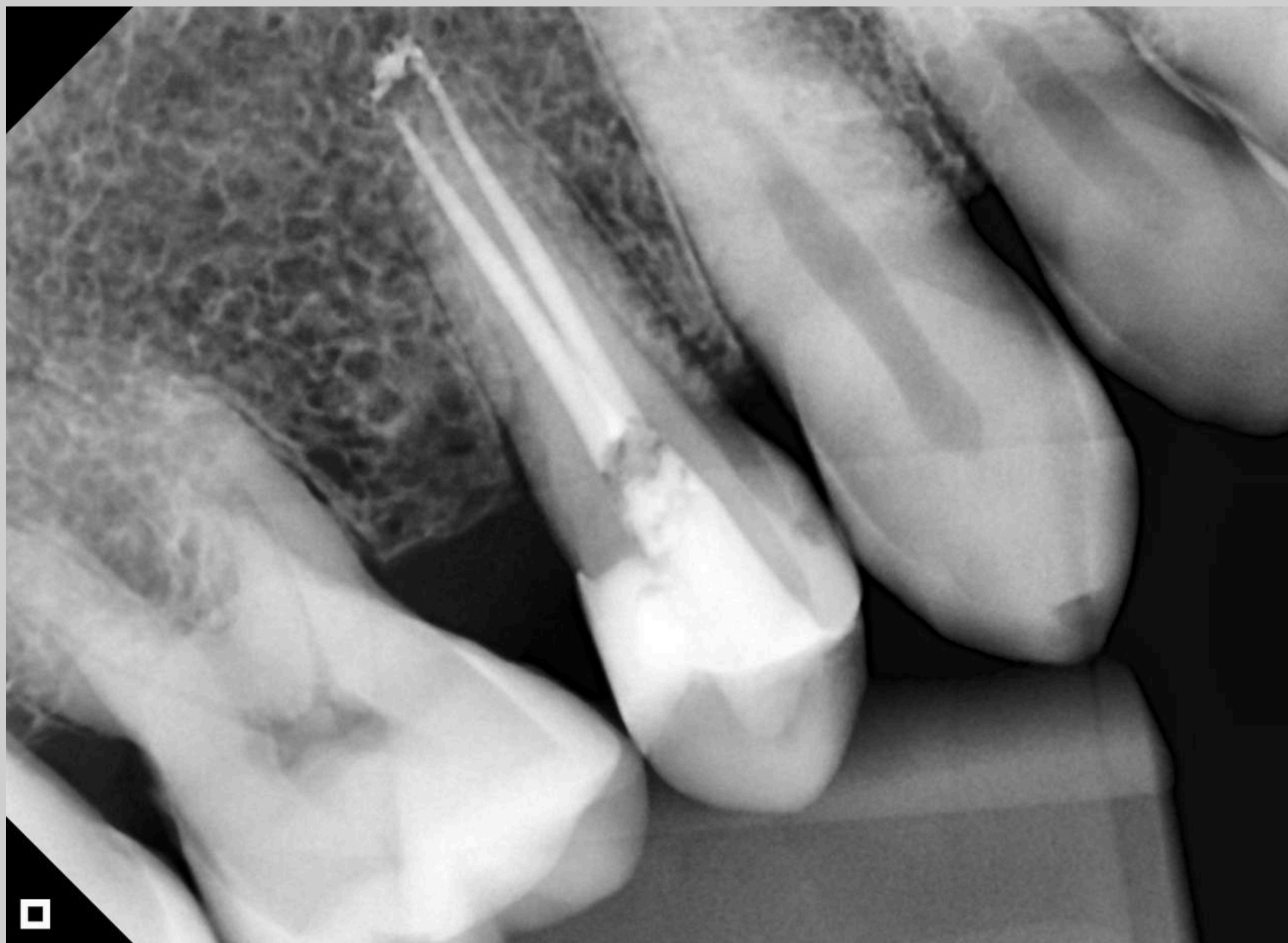
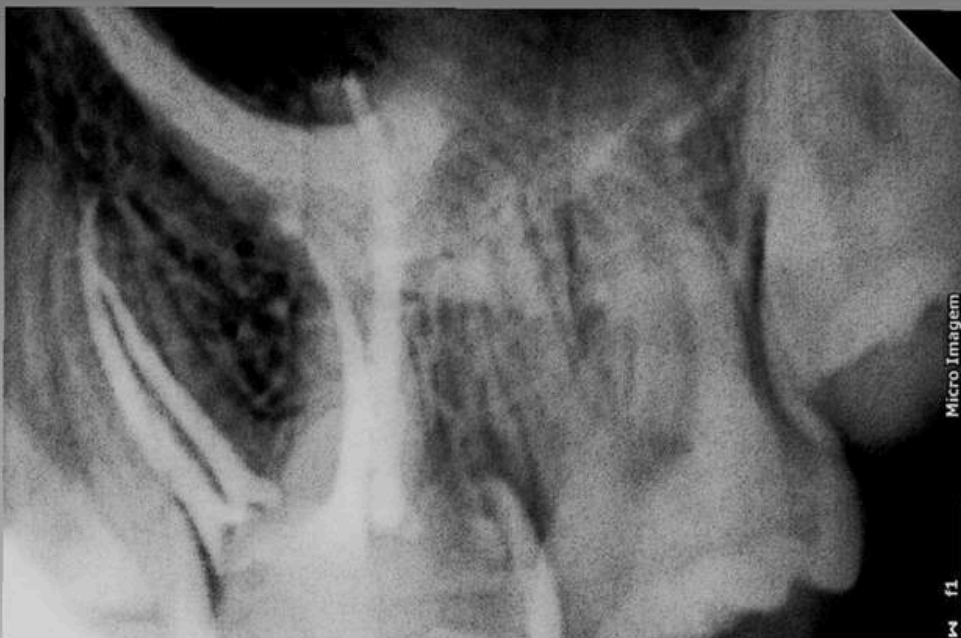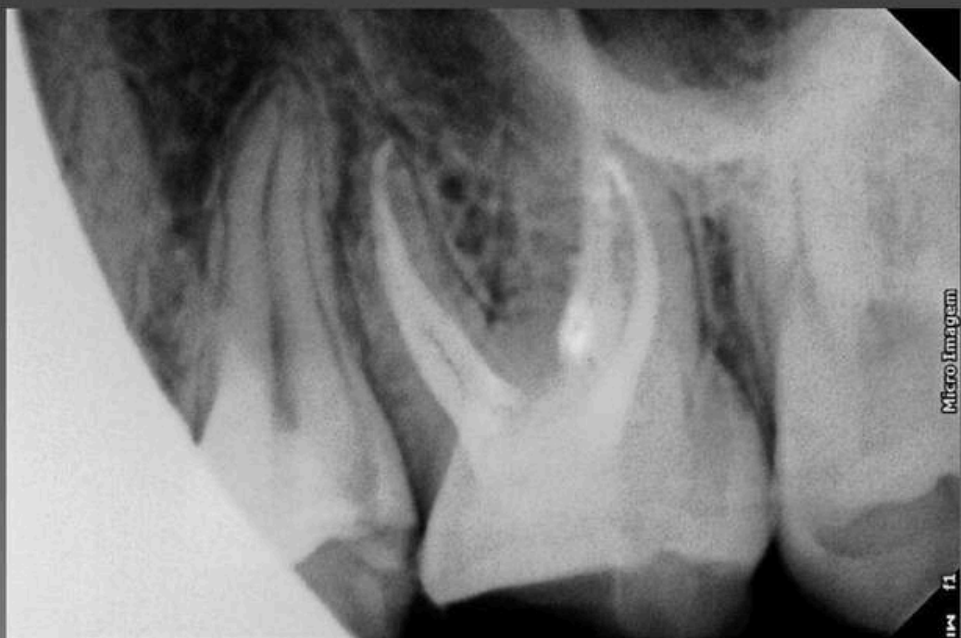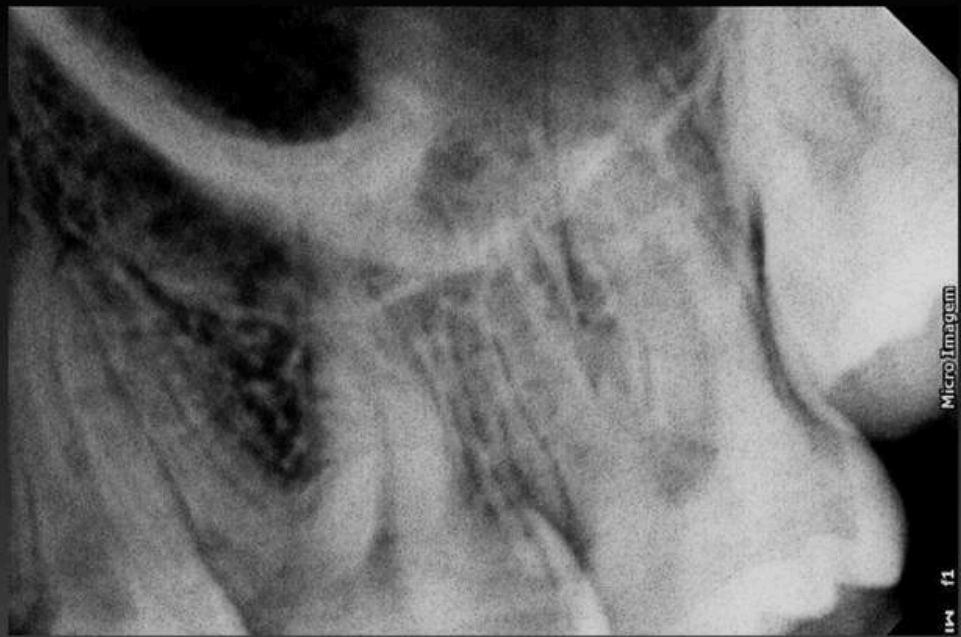Note regressão da lesão, 20 dias após a obturação.



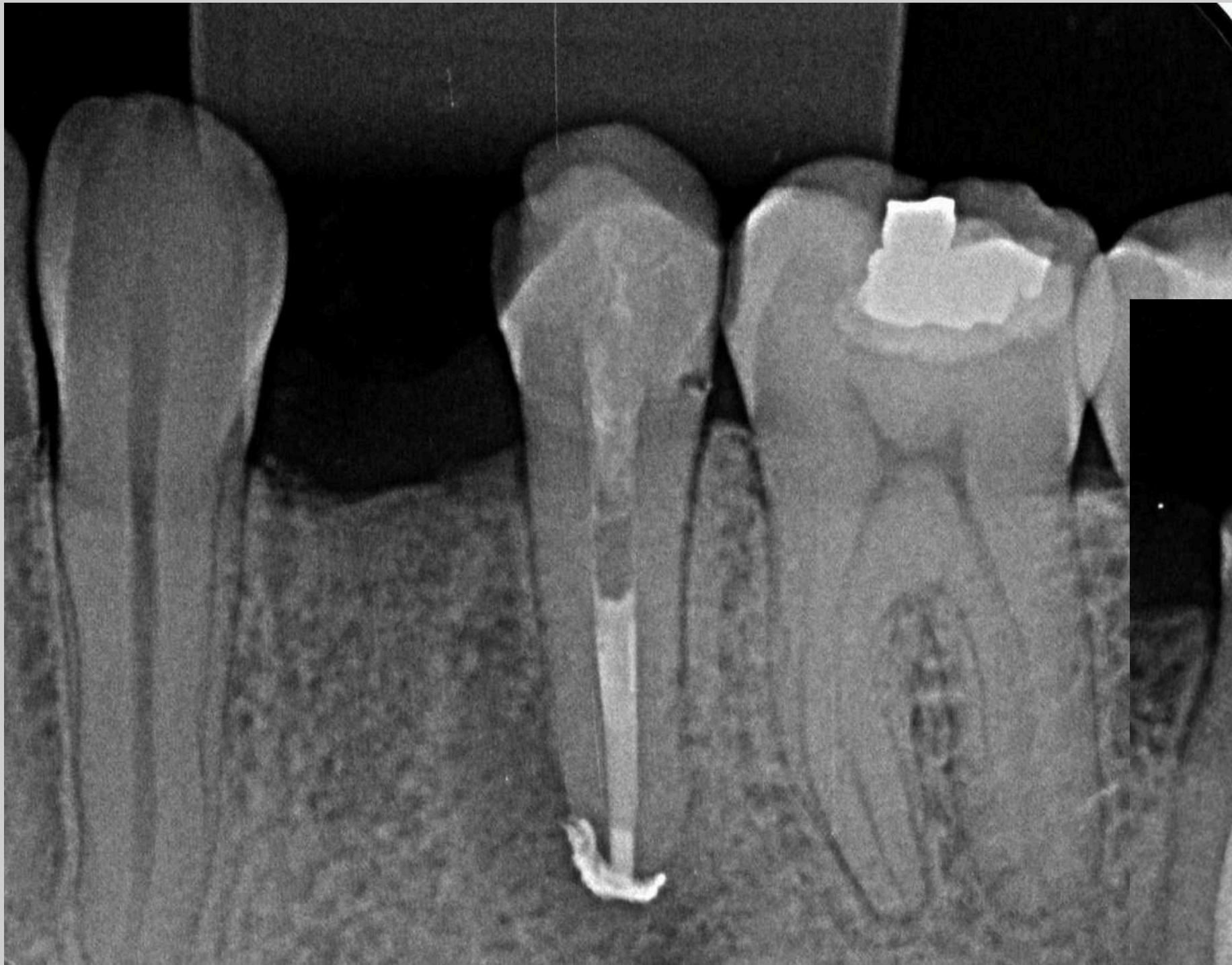Elemento 16



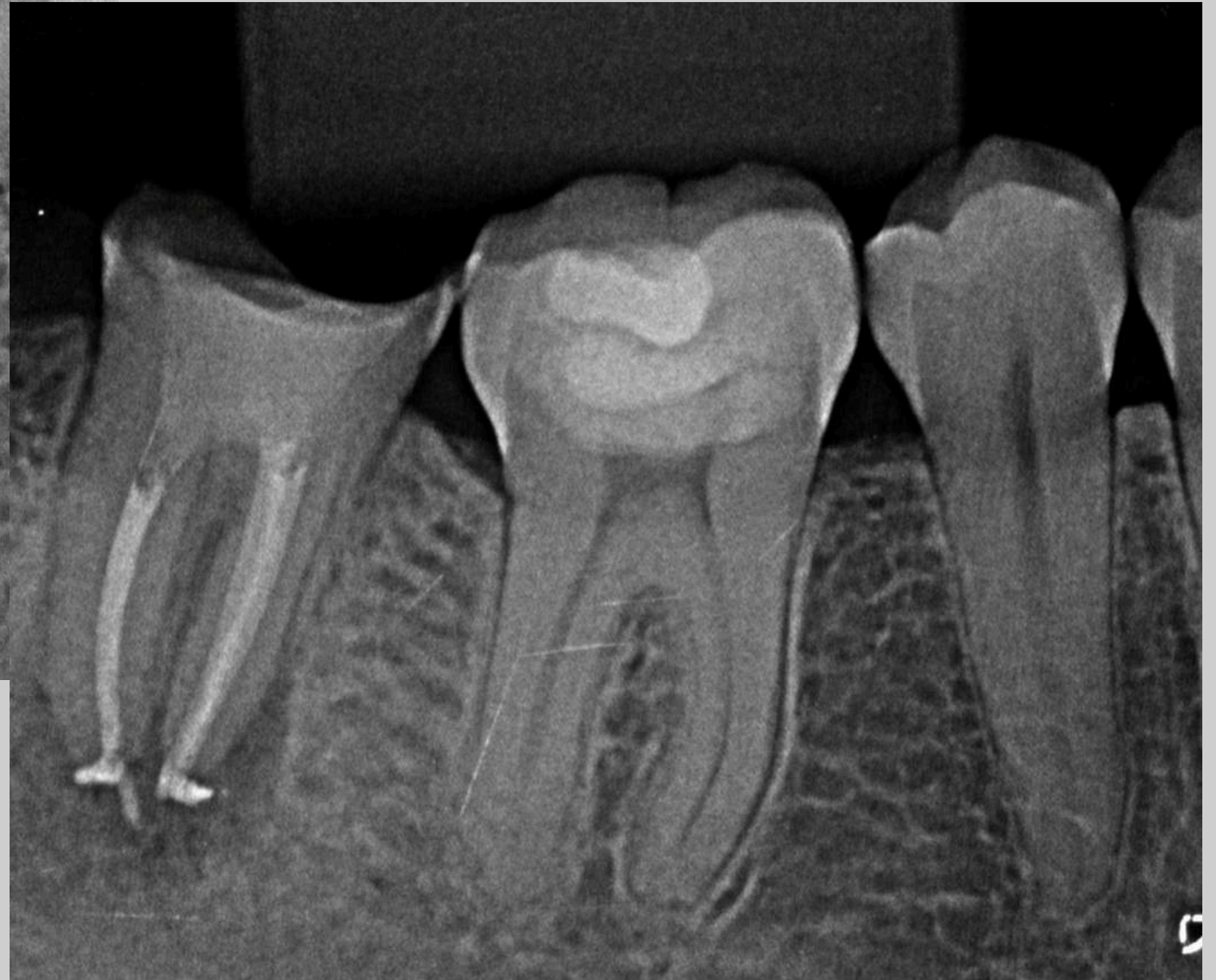Retratamento elemento 13

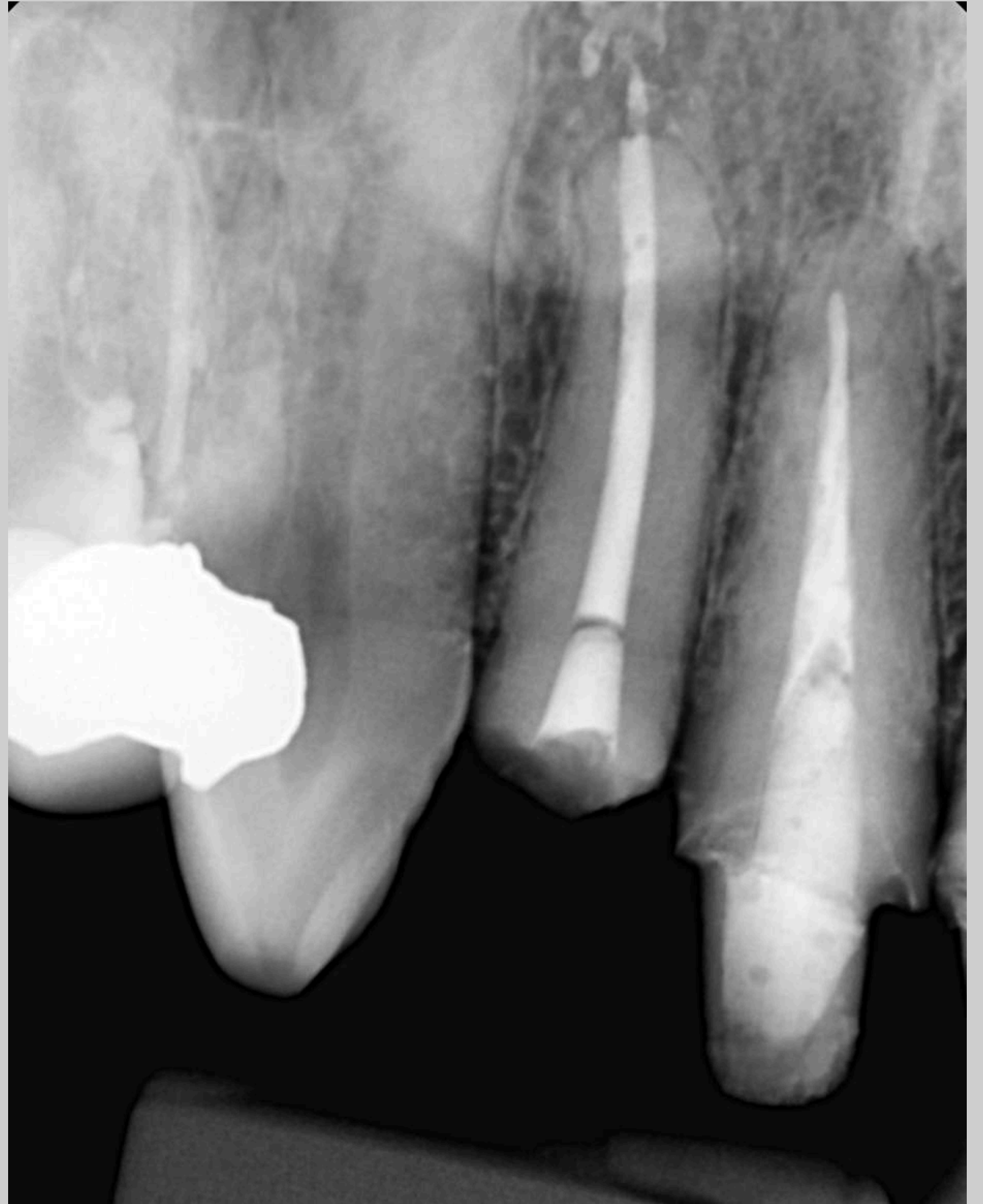
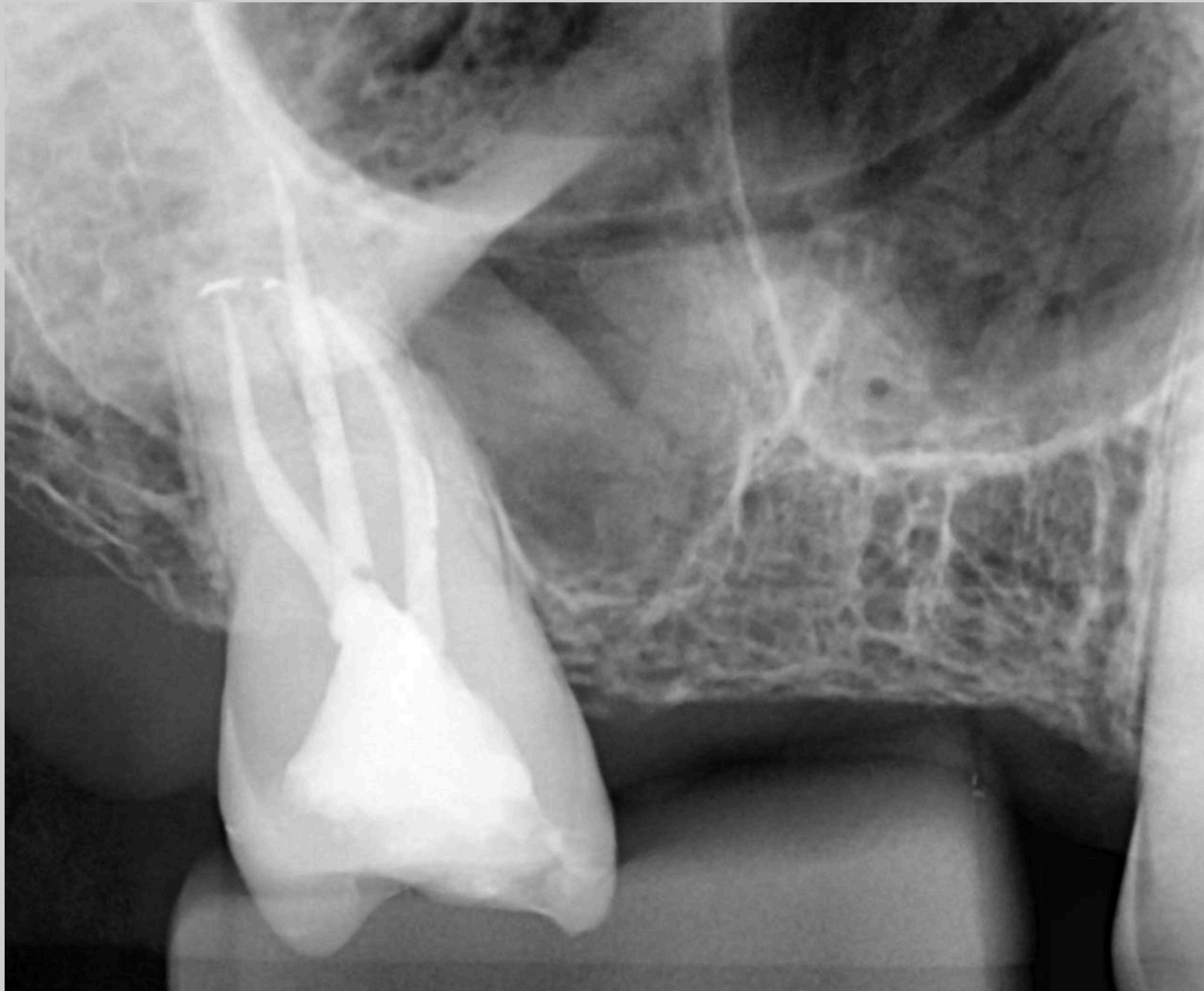
Localização e tratamento do quarto canal.

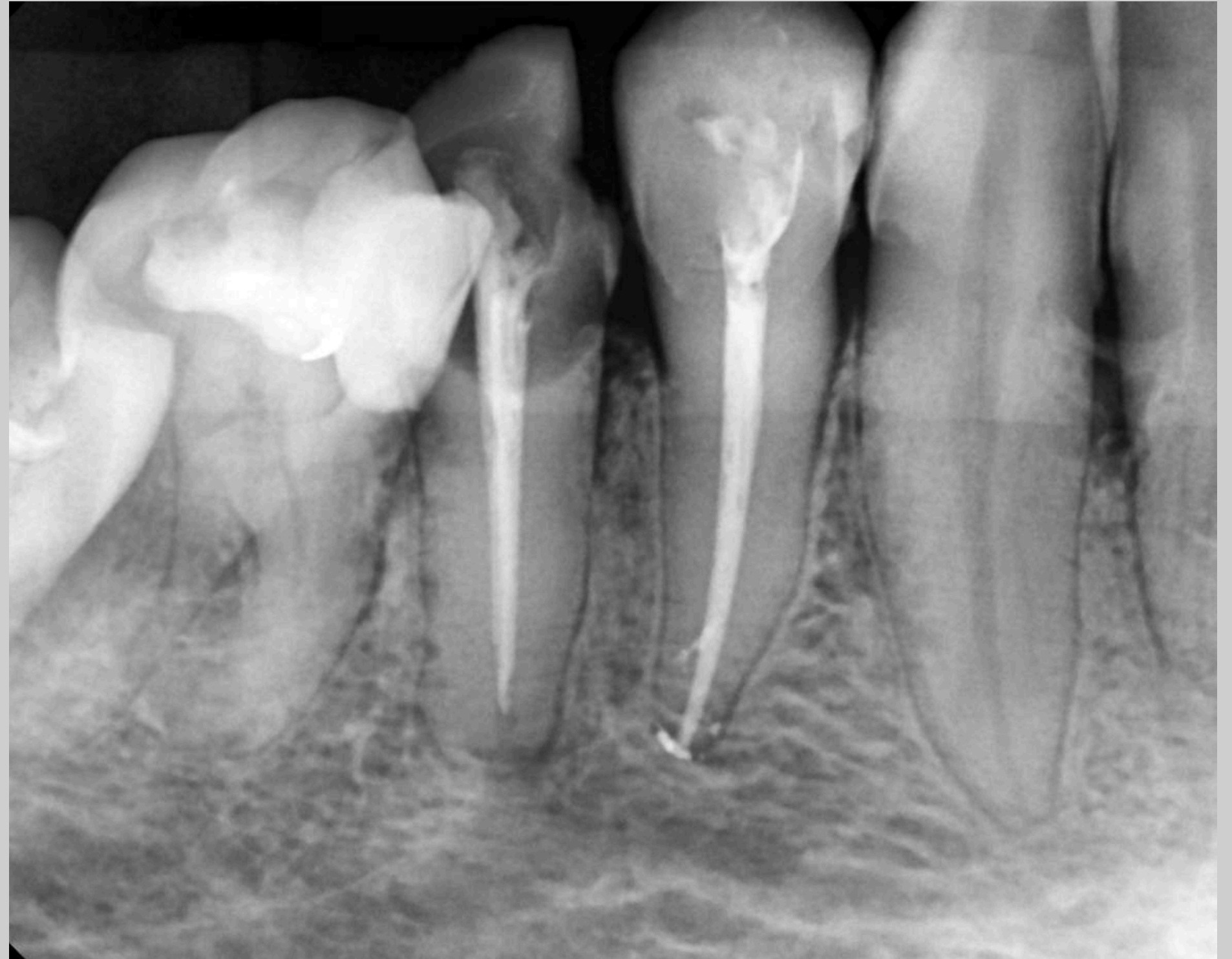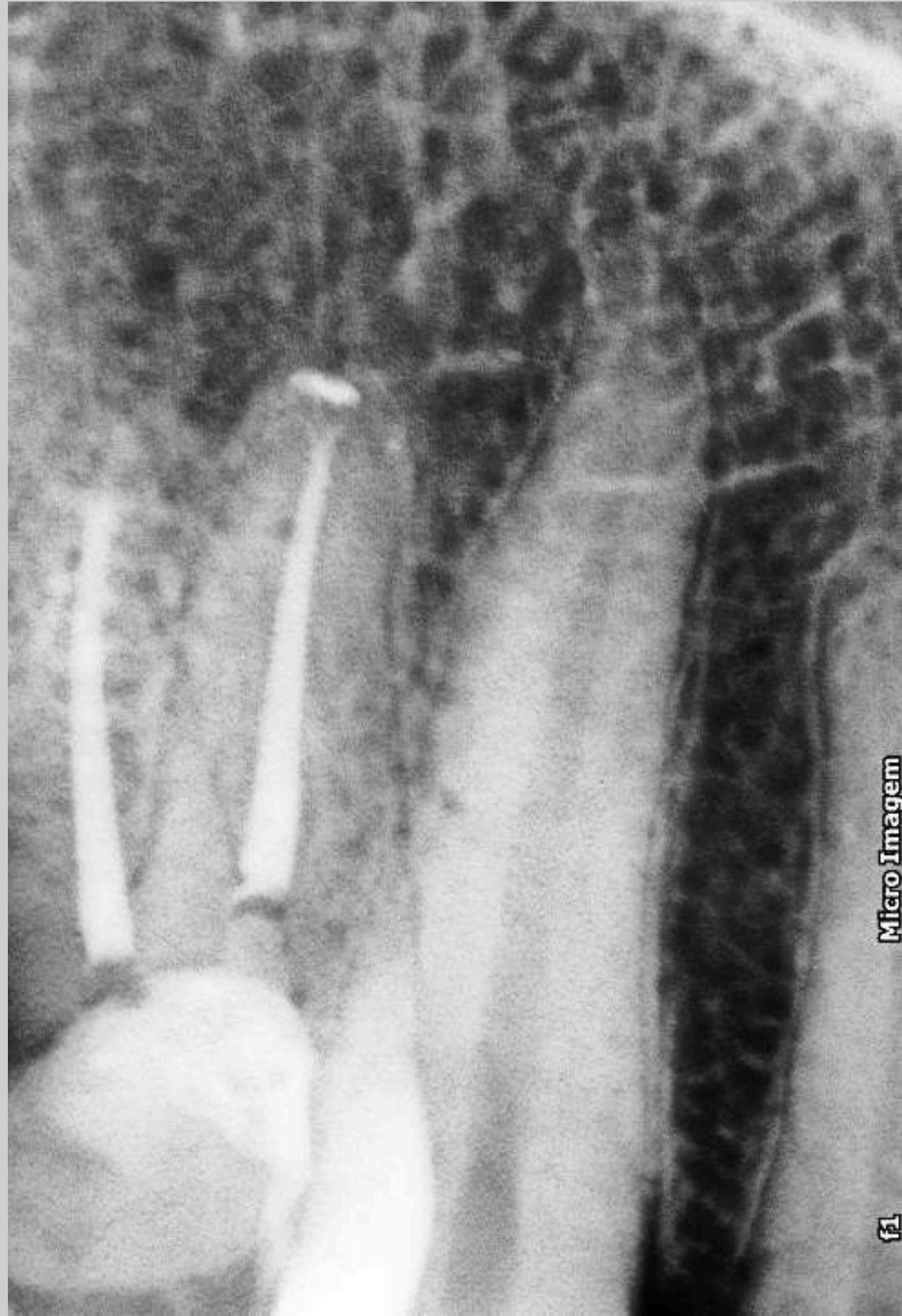


Quando solicitado, dente
preparado para pino.

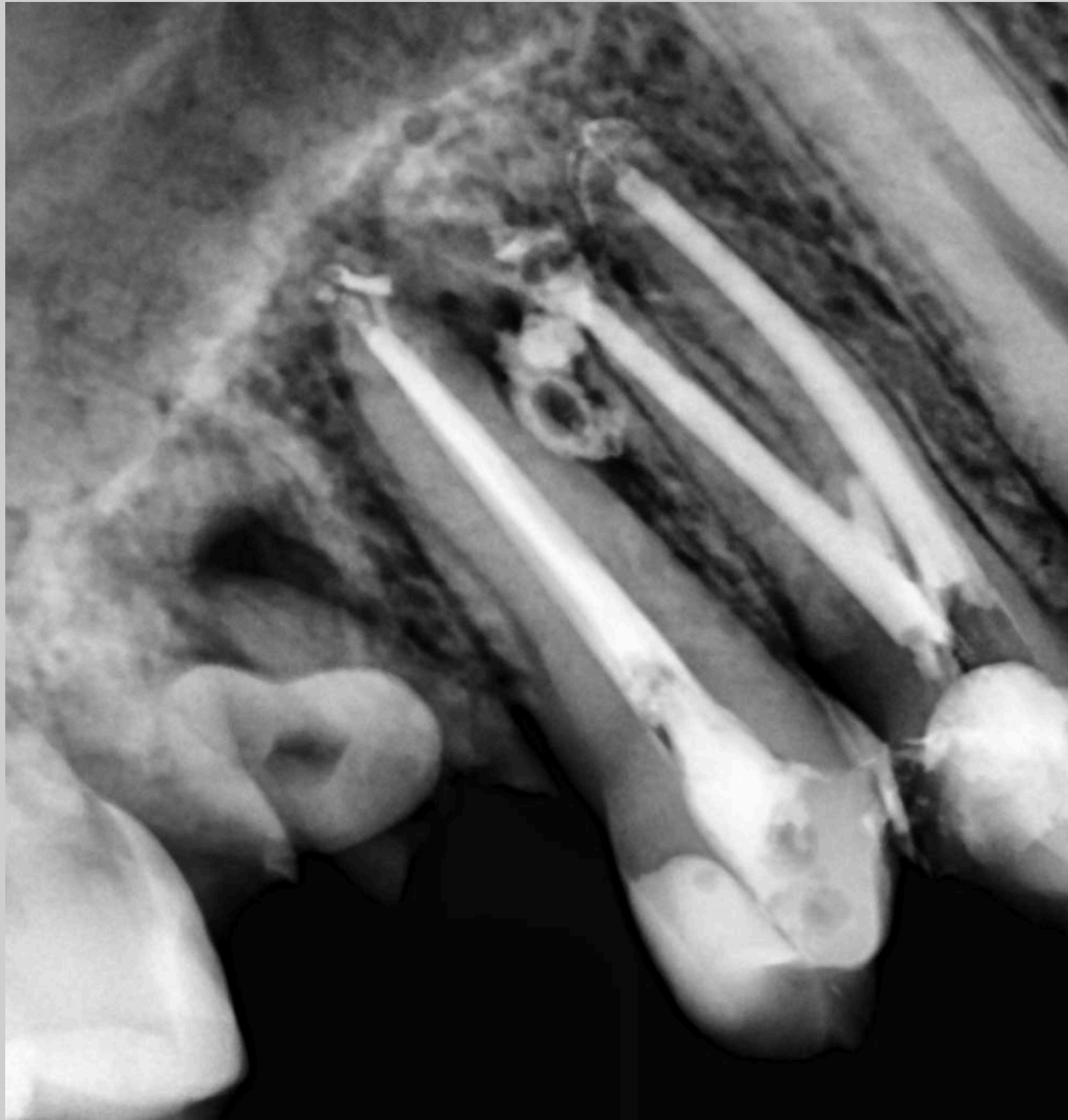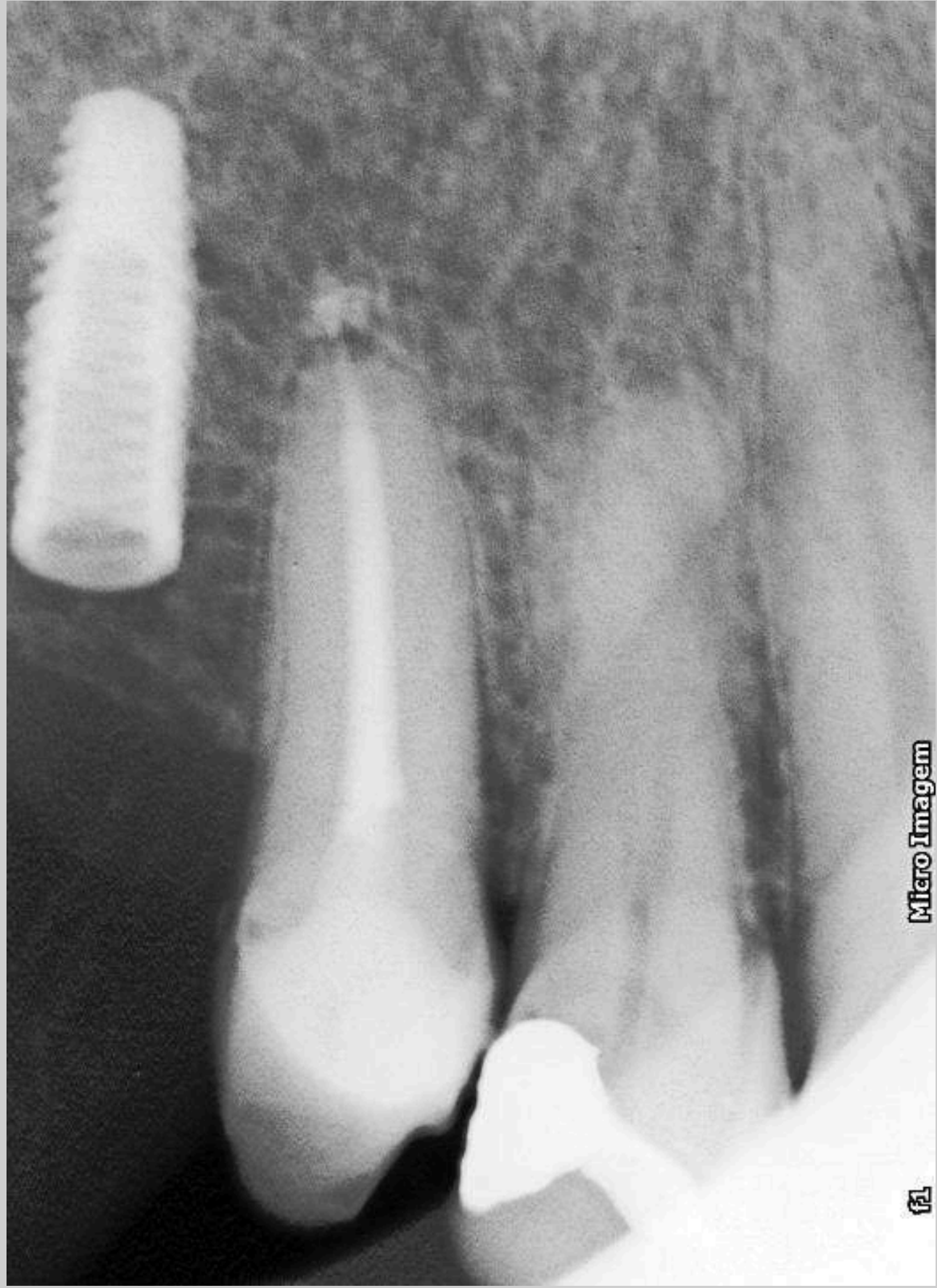



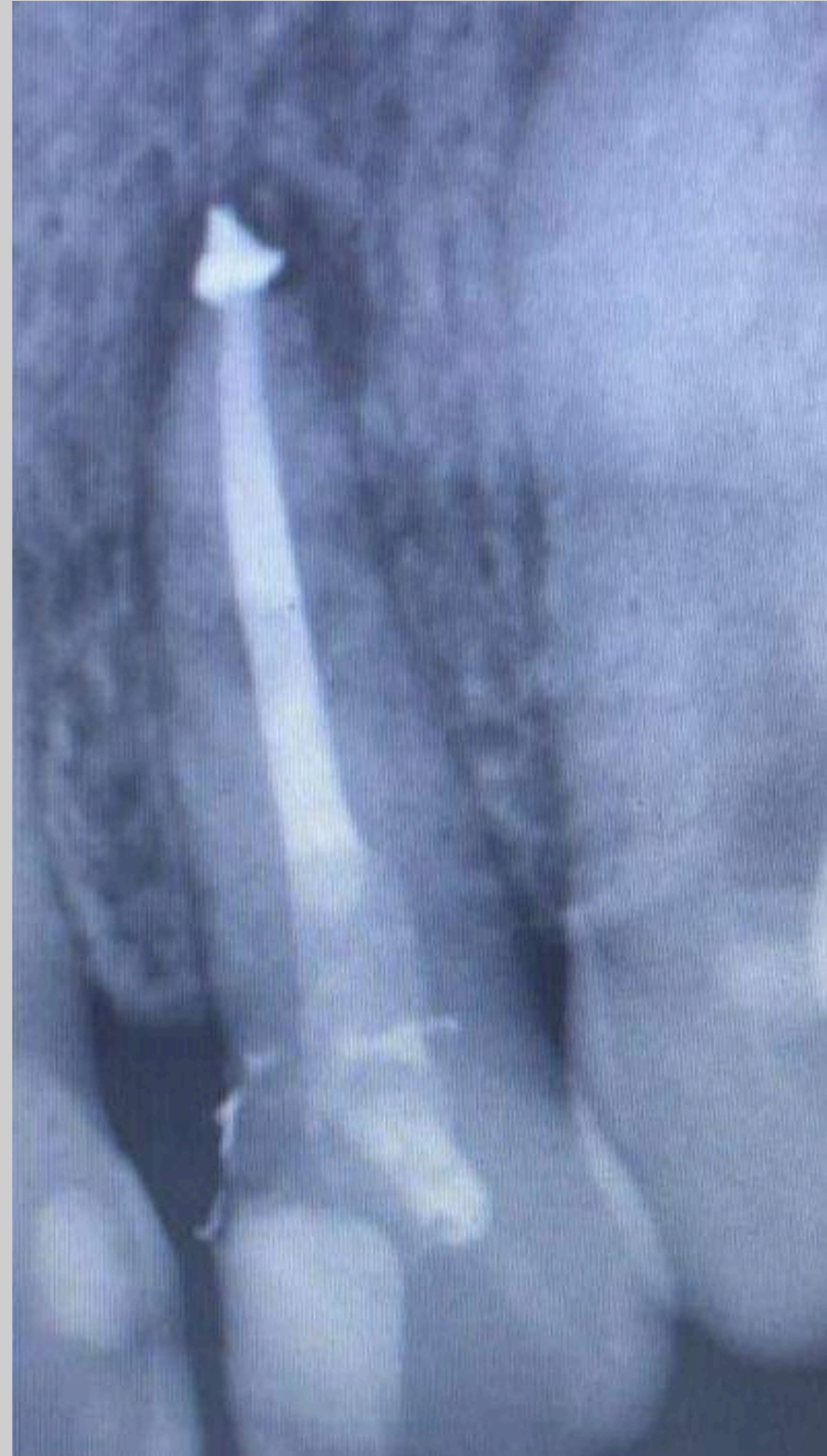
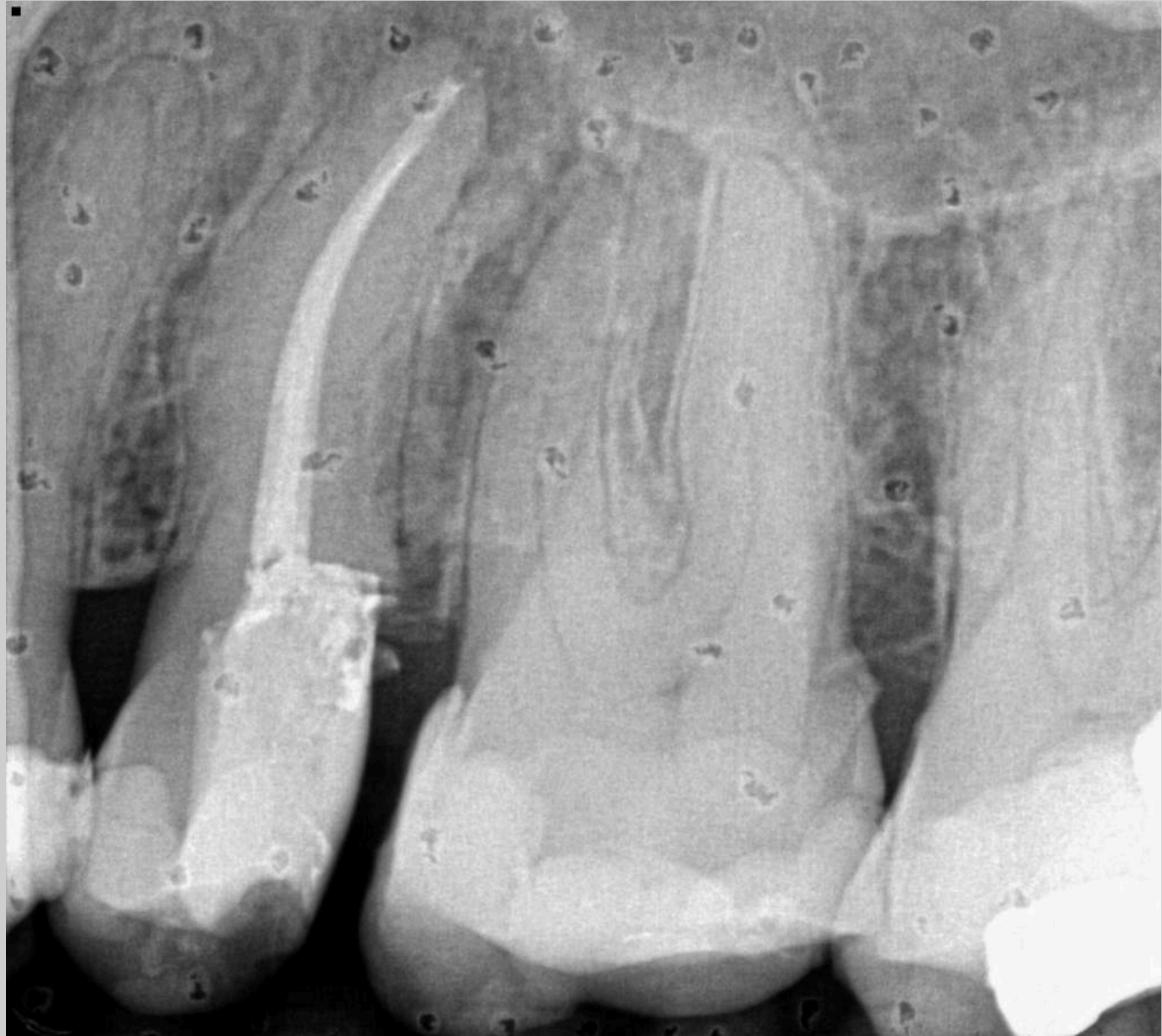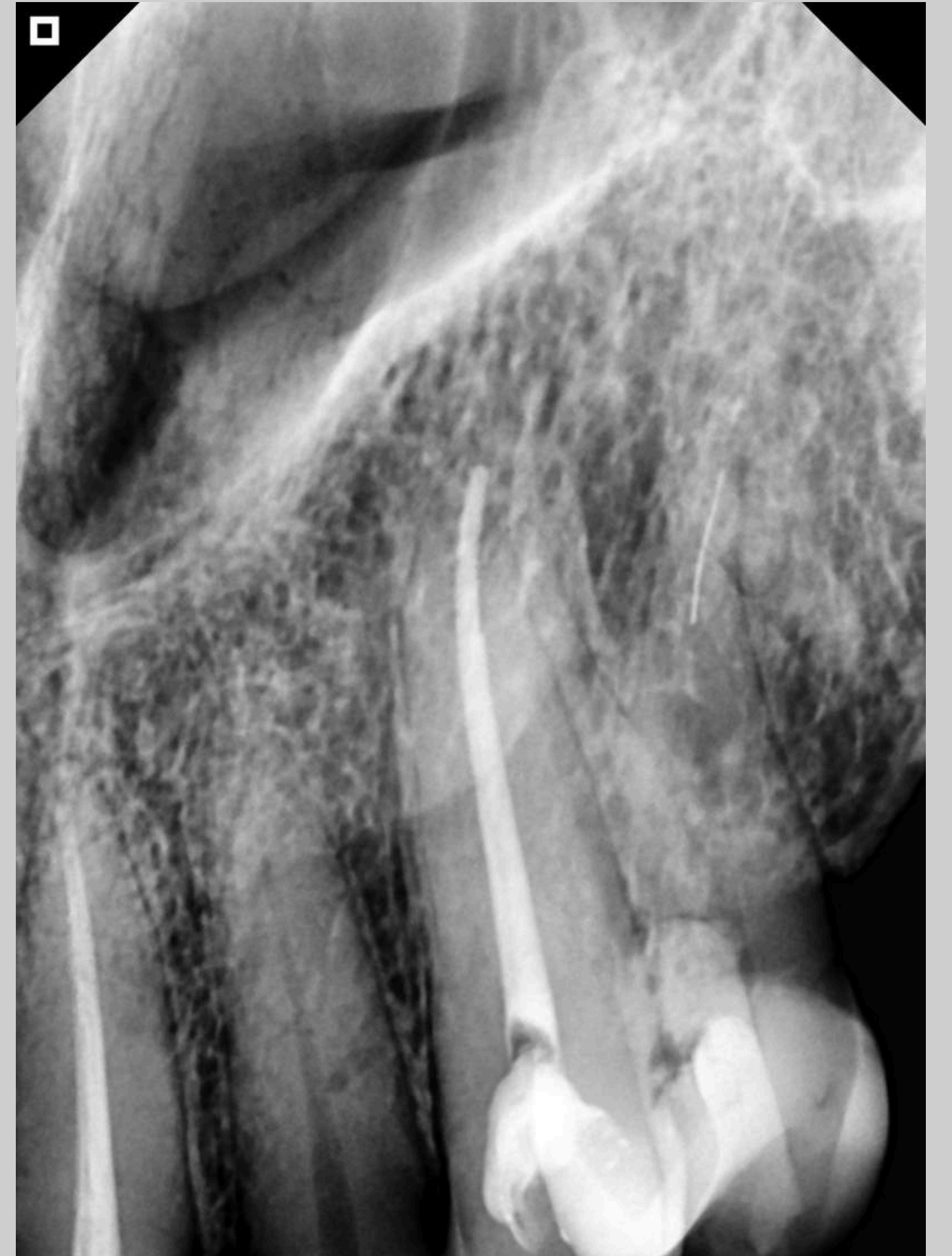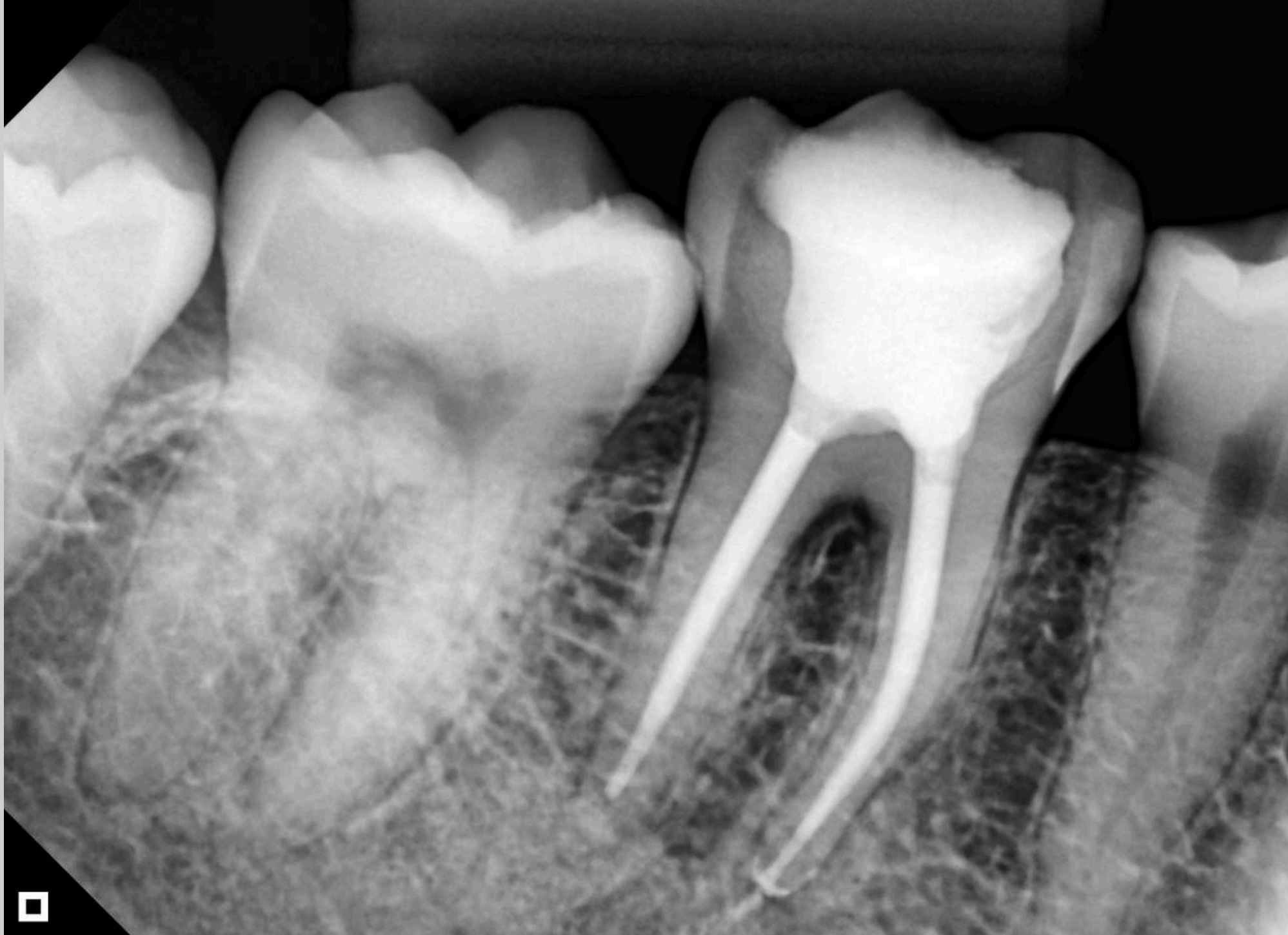Elemento 12

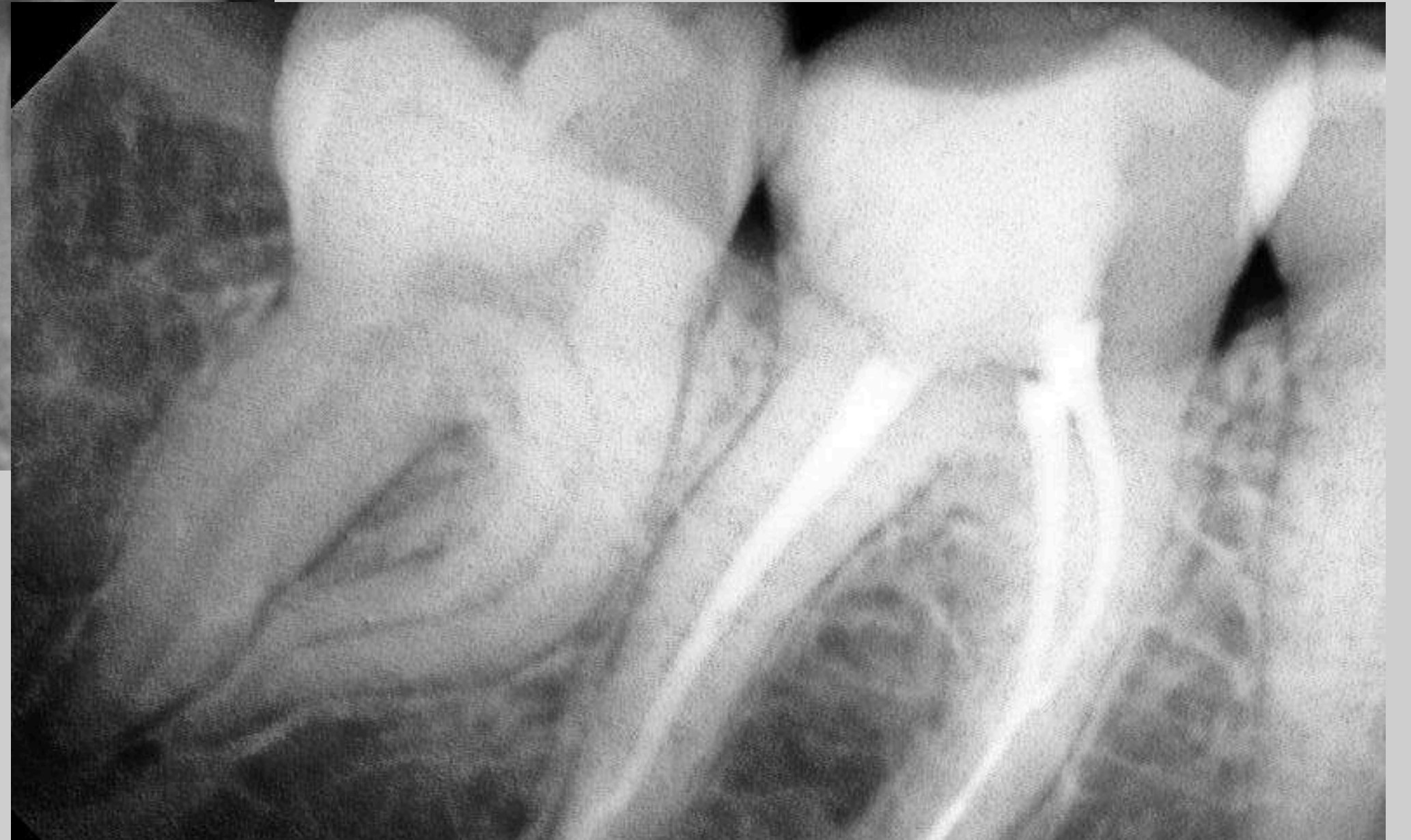
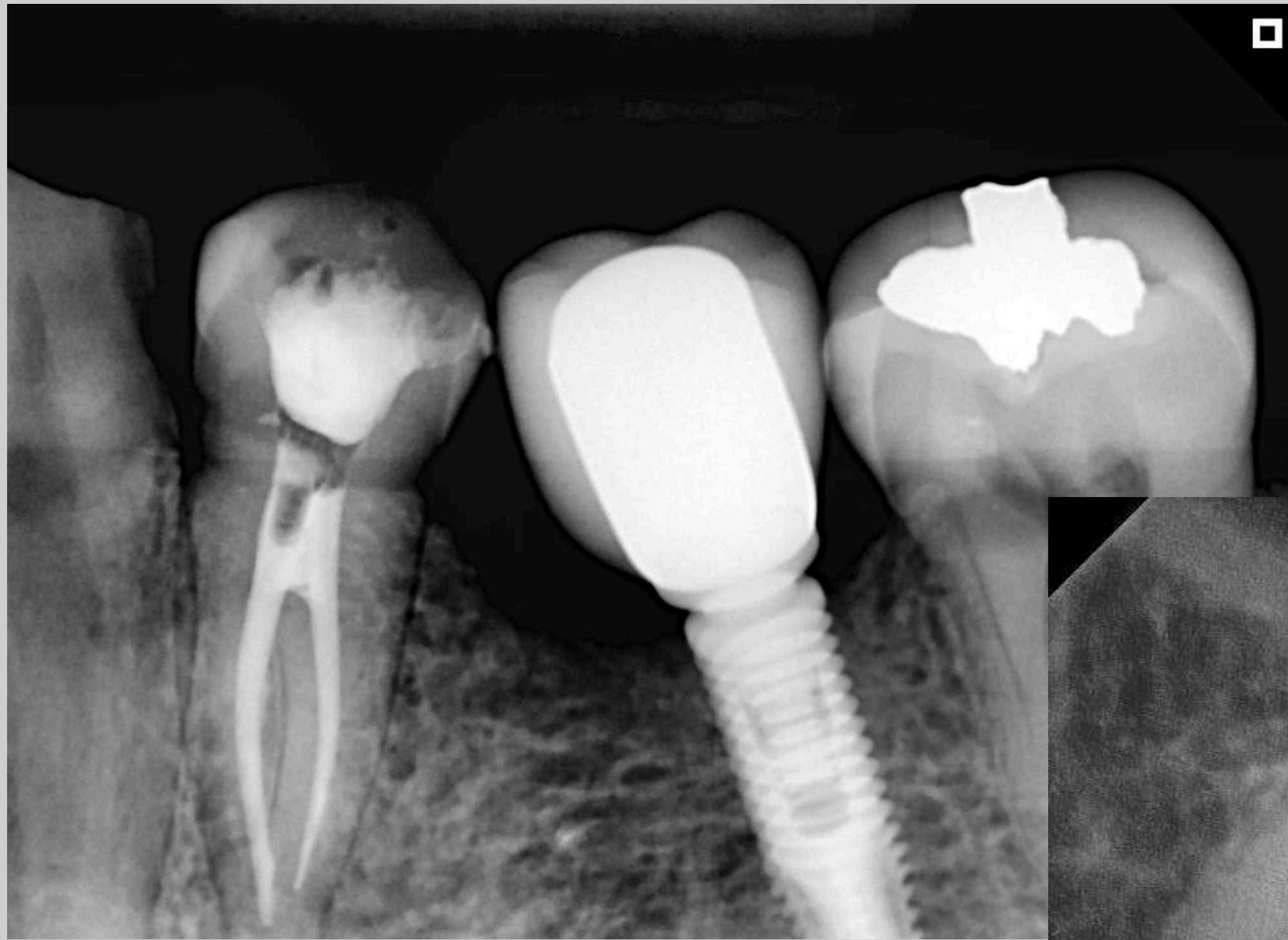


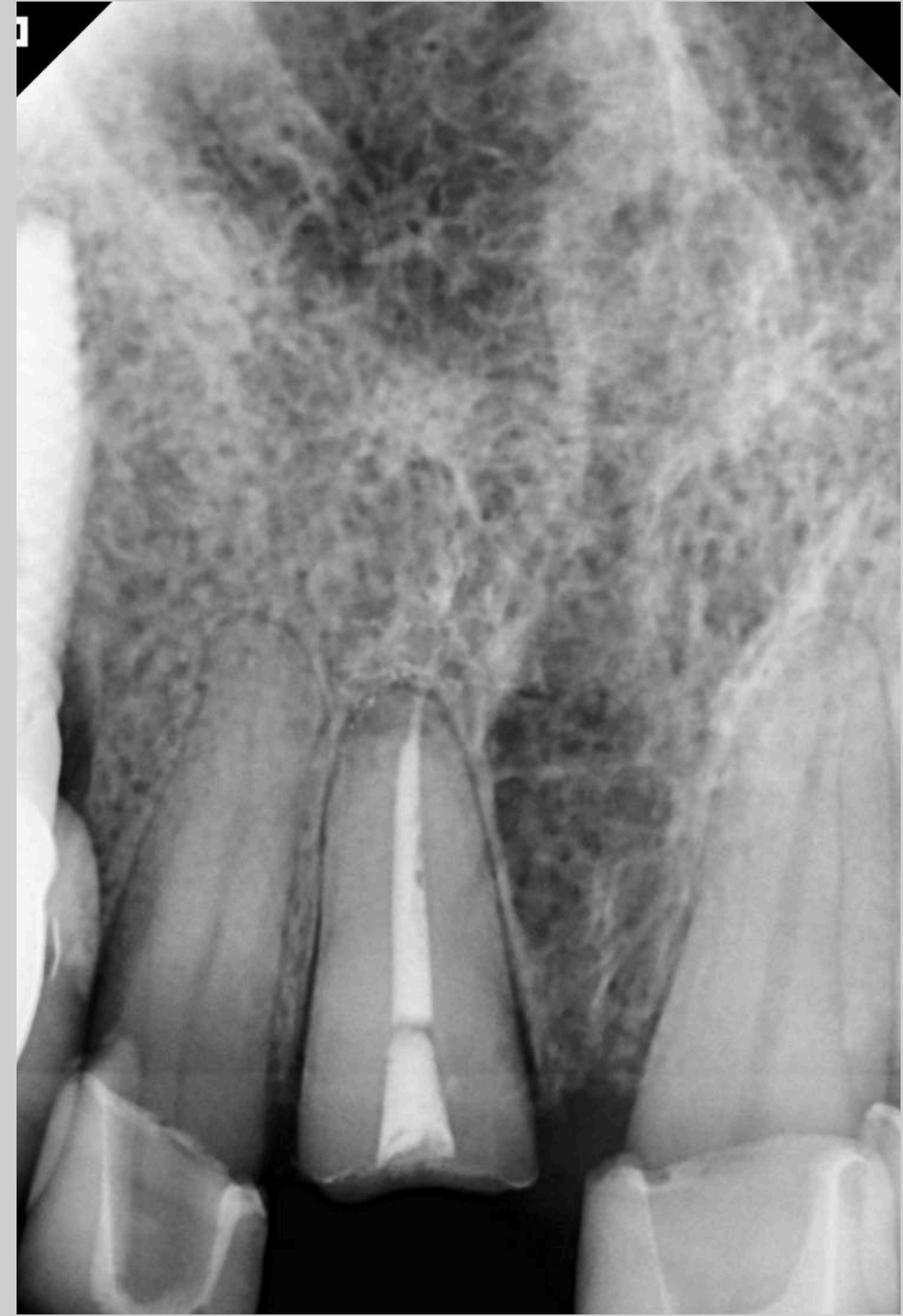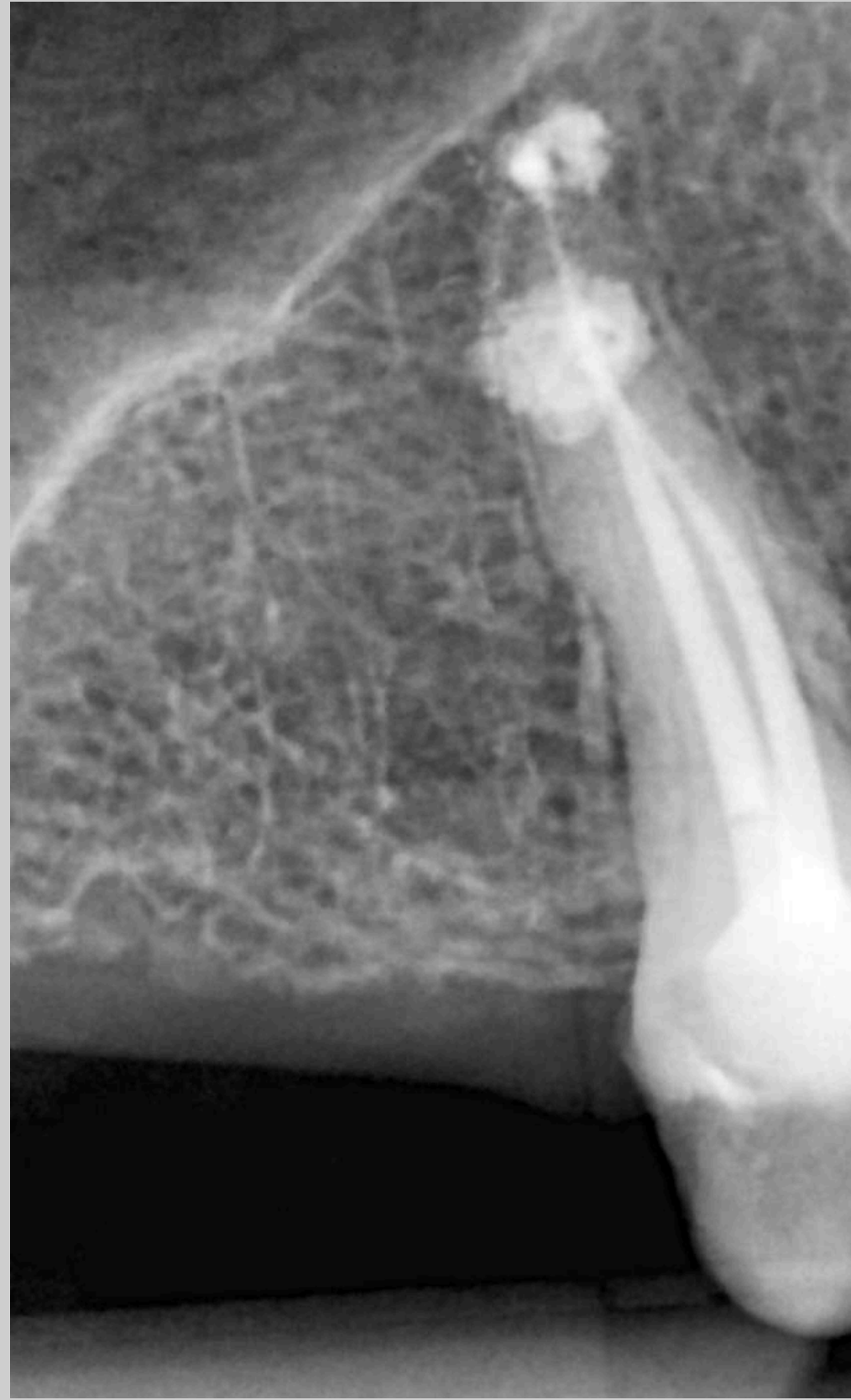Elemento 44

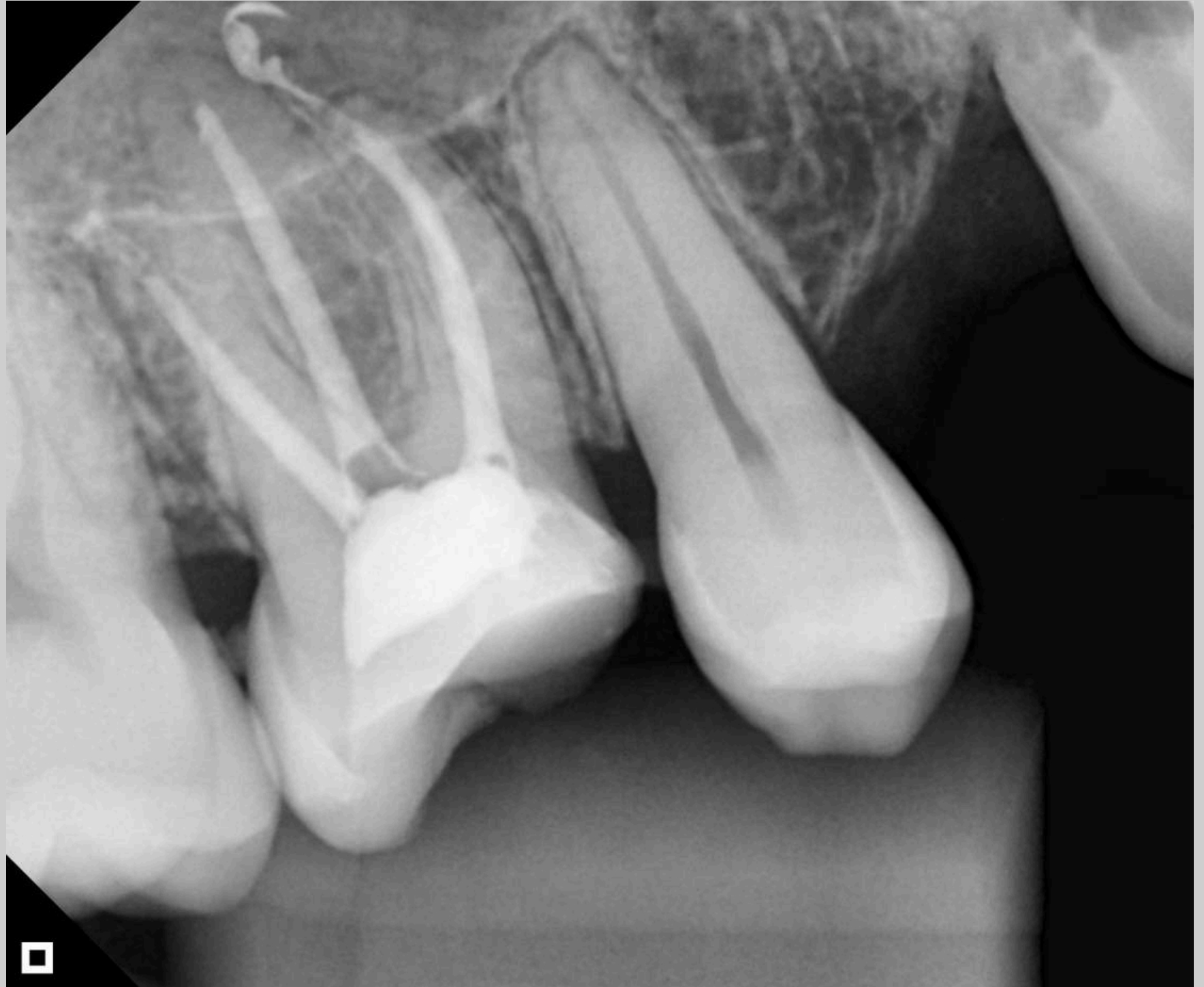
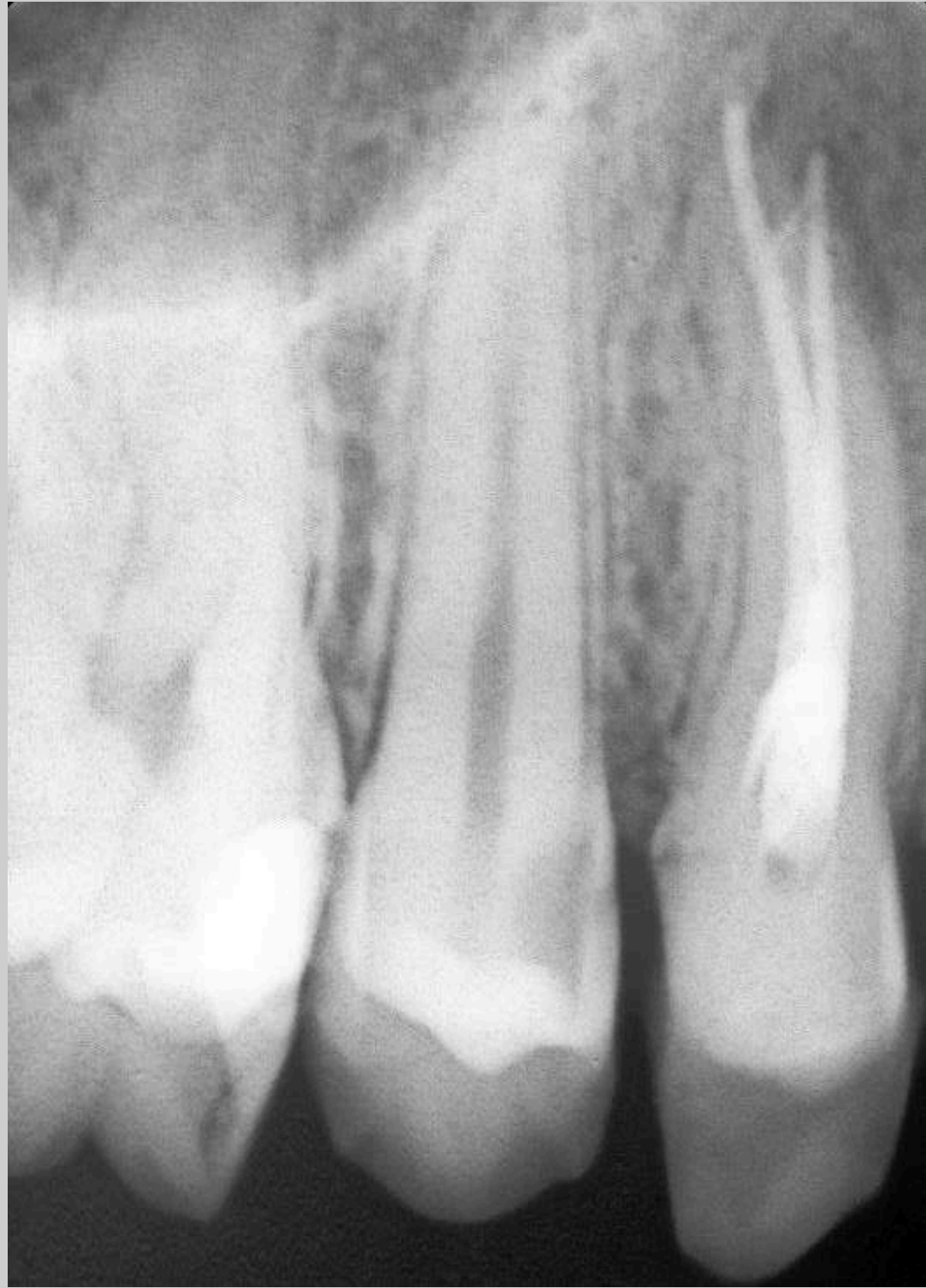










□

